

(19) World Intellectual Property Organization  
International Bureau



(43) International Publication Date  
13 March 2008 (13.03.2008)

PCT

(10) International Publication Number  
**WO 2008/031038 A2**

(51) International Patent Classification:  
A61K 49/00 (2006.01)

Skymark Avenue, Suite 306, Mississauga, Ontario L4W 4L5 (CA).

(21) International Application Number:  
PCT/US2007/077892

(72) Inventors; and

(75) Inventors/Applicants (for US only): **GOLJANIN, Dragan** [IL/US]; 190 Antlers Drive, Rochester, New York 14618 (US). **BRZOZOWSKI, Lukasz** [CA/CA]; 219 Fort York Boulevard, #703, Toronto, Ontario M5V 1B1 (CA). **WOOD, Ronald** [US/US]; 71 Wilshire Road, Rochester, New York 14618 (US).

(22) International Filing Date:  
7 September 2007 (07.09.2007)

(25) Filing Language: English

(26) Publication Language: English

(74) Agents: **HYMAN, Laurence J.** et al.; Townsend and Townsend and Crew LLP, Two Embarcadero Center, 8th Floor, San Francisco, California 94111 (US).

(30) Priority Data:  
60/843,175 7 September 2006 (07.09.2006) US  
11/851,312 6 September 2007 (06.09.2007) US

(81) Designated States (unless otherwise indicated, for every kind of national protection available): AE, AG, AL, AM, AT, AU, AZ, BA, BB, BG, BH, BR, BW, BY, BZ, CA, CH, CN, CO, CR, CU, CZ, DE, DK, DM, DO, DZ, EC, EE, EG, ES, FI, GB, GD, GE, GH, GM, GT, HN, HR, HU, ID, IL, IN, IS, JP, KE, KG, KM, KN, KP, KR, KZ, LA, LC, LK, LR, LS, LT, LU, LY, MA, MD, ME, MG, MK, MN, MW,

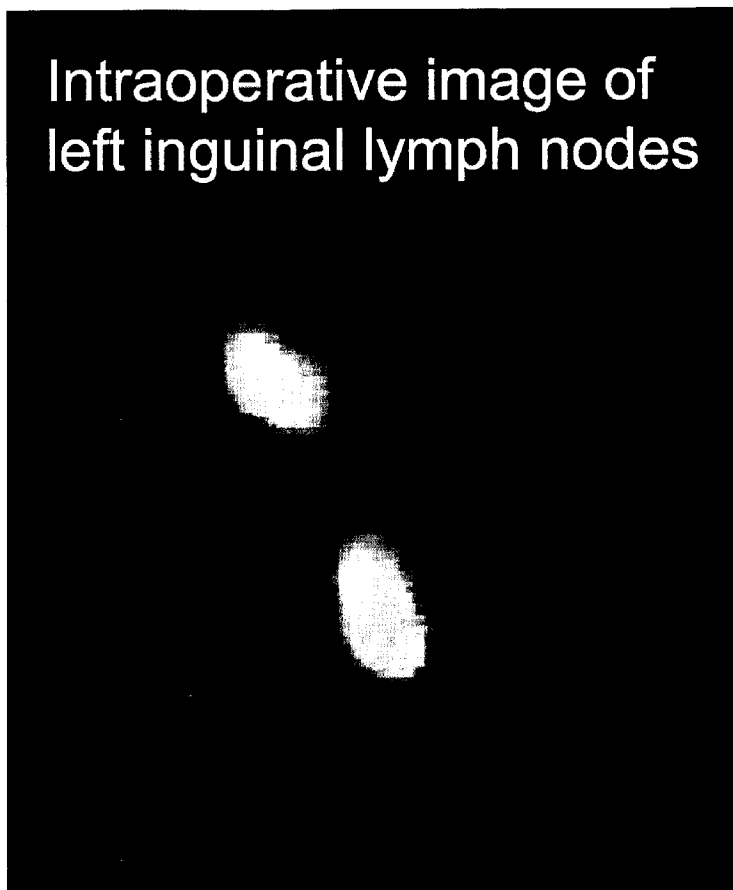
(71) Applicants (for all designated States except US): **UNIVERSITY OF ROCHESTER MEDICAL CENTER** [US/US]; Office of Technology Transfer, 601 Elmwood Avenue, Box OTT, Rochester, New York 14642 (US). **NOVADAQ TECHNOLOGIES, INC.** [CA/CA]; 2585

[Continued on next page]

(54) Title: PRE- AND INTRA-OPERATIVE LOCALIZATION OF PENILE SENTINEL NODES

(57) Abstract: The invention provides methods for pre- and intra- operatively localizing penile sentinel lymph nodes by injection of fluorescent dyes into penile tumors.

Intraoperative image of  
left inguinal lymph nodes



WO 2008/031038 A2



MX, MY, MZ, NA, NG, NI, NO, NZ, OM, PG, PH, PL, PT, RO, RS, RU, SC, SD, SE, SG, SK, SL, SM, SV, SY, TJ, TM, TN, TR, TT, TZ, UA, UG, US, UZ, VC, VN, ZA, ZM, ZW.

European (AT, BE, BG, CH, CY, CZ, DE, DK, EE, ES, FI, FR, GB, GR, HU, IE, IS, IT, LT, LU, LV, MC, MT, NL, PL, PT, RO, SE, SI, SK, TR), OAPI (BF, BJ, CF, CG, CI, CM, GA, GN, GQ, GW, ML, MR, NE, SN, TD, TG).

**(84) Designated States** (*unless otherwise indicated, for every kind of regional protection available*): ARIPO (BW, GH, GM, KE, LS, MW, MZ, NA, SD, SL, SZ, TZ, UG, ZM, ZW), Eurasian (AM, AZ, BY, KG, KZ, MD, RU, TJ, TM),

**Published:**

— *without international search report and to be republished upon receipt of that report*

## PRE- AND INTRA- OPERATIVE LOCALIZATION OF PENILE SENTINEL NODES

### CROSS-REFERENCES TO RELATED APPLICATIONS

5 [0001] This disclosure claims the benefit of U.S. Application No. 11/851,312, filed September 6, 2007, and of U.S. Provisional Application No. 60/843,175, filed September 7, 2006, the contents of both of which are incorporated herein by reference.

### STATEMENT AS TO RIGHTS TO INVENTIONS MADE UNDER 10 FEDERALLY SPONSORED RESEARCH AND DEVELOPMENT

[0002] NOT APPLICABLE

### REFERENCE TO A "SEQUENCE LISTING," A TABLE, OR A COMPUTER PROGRAM LISTING APPENDIX SUBMITTED ON A COMPACT DISK.

15 [0003] NOT APPLICABLE

### BACKGROUND OF THE INVENTION

[0004] A variety of medical techniques suitable for imaging biological tissues and organs are known. These include traditional x-rays, ultra-sound, magnetic resonance imaging, and  
20 computerized tomography.

[0005] A variety of dyes useful for medical imaging have been described, including radio opaque dyes, fluorescent dyes, and colorimetric dyes (see e.g., U.S. Patent Nos. 5,699,798; 5,279,298; 6,351,663). Imaging techniques and systems using fluorescent dyes have been described for the heart and eye (see, e.g., U.S. Patent No. 5,279,298). Some dyes can serve  
25 both an imaging function and a therapeutic function (see, e.g. U. S. Patent No. 6,840,933). Some specific neuronal imaging agents have been used to visualize tissue in the central nervous system. Tracer uptake and transport has been demonstrated in different studies using various routes of administration including antegrade, retrograde and combined routes (Jones et al. 1978, *Annu Rev Neurosci.*, 1:215; Rosina A., 1982, *Neurosci Lett.* 33(3):217; Illing RB, et al., 1985, *Neuroscience* 14(2):455; Sloniewski P, et al., 1985, *Neurosci Lett.* 60(2):189;  
30

and Schmued et al., 1986, *Brain Res.* 377(1):147). After appropriate time for endo/pinocytosis, perineural lymphatic and axonal transport, which generally measures 0.5-2 mm per hour, tracers were visually detected using ultraviolet or visible light (Bentivoglio et al., 1980, *Neurosci Lett.* 18(1):19; Minciacchi D et al., 1991, *J Neurosci Methods.* 38(2-3):183). Tracers such as Indocyanine Green, Fast Blue, and Fluorogold, have been used in mammals without evidence of neuronal toxicity several months after the treatment (Thielert et al., 1993, *J Comp Neurol.* 337(1):113; Yeterian et al., 1994, *Exp Brain Res.* 99(3):383; vogt Weisenhorn et al., 1995, *J Comp Neurol.* 362(2):233). Marangos et al. labeled the auditory nerve using Fluorogold and Fast Blue in rats and monkeys by suctioning out perilymph and filling the cochlea with neuronal tracers to identify the nerve and cochlear brain stem nucleus for the positioning of electrodes for an auditory neuroprosthesis (Marangos N, et al., 2001, *Hear Res.* 162(1-2):48).

**[0006]** According to the American Cancer Society, only some 1,500 cases are diagnosed a year in the U.S., accounting for only 0.2% of cancers in men in the U.S. Although penile cancer is relatively uncommon among American and European men, it is much more common in Africa and South America, where it accounts for 10 % of all male cancers. While definitive causes of penile cancer are not known, there are some known risk factors. One such risk factor is infection with human papillomavirus. In a report available on-line as of this writing, Senba et al., *J Med Virol.* 2006, 78(10):1341-6, reported the detection of human papillomavirus DNA in 80 % of 65 samples of penile cancer from Thai men, with HPV-18 being the most prevalent. Another, in uncircumcised males, is the buildup of secretions under the foreskin.

**[0007]** According to the American Cancer Society, some 95 % of penile cancers are squamous cell carcinomas and usually develop on the foreskin (if the male is uncircumcised) or the glans. Typically, the patient presents with a rash, bumps, ulcer or discharge, and the cancer is diagnosed by microscopic examination of biopsied tissue. Lymph node metastasis is a crucial prognostic factor in penile cancer. About 50% of patients with palpable lymph nodes will have metastases, and about 20% of patients without enlarged lymph nodes will have lymphatic spread (Hardner, GJ, *J Urol*, 108:428ff (1972); Kossow, JH, *Urology*, 2:169ff (1973); McDougal, WS, *J Urol* 136:38ff (1986)). Successful sentinel lymph node dissection (SLND) is predicated on precise detection of the lymphatic drainage into sentinel nodes. According to the National Cancer Institute, when diagnosed early (stage 0, stage I, and stage II), penile cancer is highly curable, but curability decreases sharply for stage III and stage IV.

Criteria for staging penile cancer are known in the art, and set forth at, e.g., *Penis: American Joint Committee on Cancer, AJCC Cancer Staging Manual*, 6th Ed., Springer, NY NY, 2002, pp. 302-8.

[0008] Unfortunately, there is significant anatomical variation in penile lymph node drainage as well as in sentinel lymph node position. In multiple cases, current dye or radionuclide lymphatic tracing methods result in identification of sentinel and some of the metastatic lymph nodes (Cabanas, RM, *Urol Clin N Am* 19:267ff (1992); Lynch, DF, Jr: *AUA update series*, 16:256 (1997)). Nevertheless these procedures are difficult, time-consuming, expensive and have low sensitivity, especially when used with methylene blue. If sentinel nodes are found without metastases this would obviate unnecessary removal of noninvolved nodes as seen in 90-95% of superficial lesions, 50-60% of T2 lesions, and 10-20% of T2b and T3 lesions (Horenblas et al., *J Urol* 155:1239-1243 (1994)). The presence of metastases will be followed by complete lymph node dissection. Current practice is to remove all inguinal or ilioinguinal lymph nodes in penile cancer surgeries, resulting in significant morbidity in more than 30% of the patients. Multiple methods, such as the use of radioactive tracers, have been used in the hope of improving the detection of sentinel nodes, see, e.g., Brennhovd et al., Sentinel node procedure in low-stage/low-grade penile carcinomas, *Scand J Urol Nephrol*. 2006; 40(3):204-7, but no method has yet emerged as a standard.

[0009] Accordingly, a need exists for improved methods of locating sentinel lymph nodes for persons with penile cancer. The present invention fills these and other needs.

#### BRIEF SUMMARY OF THE INVENTION

[0010] The invention provides methods of localizing before or during a surgical operation a lymph node draining a penile tumor having edges and a base in a subject, comprising, about 10 minutes to about 24 hours prior to the surgical operation, injecting the edges or the base of the tumor of the subject with a dye which fluoresces at an emission wavelength when the dye is contacted with an excitation wavelength; exposing the lymph node to illumination comprising the excitation wavelength, thereby causing the fluorescent dye to fluoresce; and, detecting the fluorescence of the dye, thereby localizing the lymph node. In some embodiments, the lymph node is a sentinel lymph node. In some embodiments, the dye is injected into the edges of the tumor. In some embodiments, the dye is injected into the base

of the tumor. In some embodiments, the lymph node is visualized on a image display. In some embodiments, the exposure of the lymph node to excitation wavelength is by a laparoscopic instrument. In some embodiments, the dye is a dye which fluoresces when exposed to near infrared light. In some embodiments, the dye is a tricarboyanine dye or an analog thereof. In some embodiments, the tricarboyanine dye is indocyanine green. In some embodiments, the subject is a human. In some embodiments, the dye is injected between about 10 minutes and 12 hours before the surgical operation. In some embodiments, the dye is injected between about 1 hour and about 6 hours before the surgical operation. In some embodiments, the dye is injected between about 1 hour and about 2 hours before the surgical operation. In some embodiments, the steps of exposing the lymph node to illumination comprising the excitation wavelength, thereby causing the fluorescent dye to fluoresce; and detecting the fluorescence of the dye, thereby localizing the lymph node, are performed during the surgical operation. In some embodiments, the surgical operation is a laparoscopic operation.

15

#### BRIEF DESCRIPTION OF THE DRAWINGS

**[0011] Figure 1.** Figure 1 shows detection of inguinal lymph nodes by near infrared fluorescence (NIRF) through the body wall of a rat in which indocyanine green had been injected into the cavernous bodies of the penis. Arrows indicate the lymphatics and the lymph nodes.

20

**[0012] Figure 2.** Figure 2 shows an intraoperative image of inguinal lymph nodes first detected by near infrared fluorescence (NIRF) through the body wall of a rat in which indocyanine green had been injected into the cavernous bodies of the penis. Arrows indicate the lymphatics and the lymph nodes.

25

#### DETAILED DESCRIPTION OF THE INVENTION

**[0013]** Lymph nodes that receive the lymph from a particular organ or region of the body are considered to "drain" that organ or region. As set forth in the Background, various techniques and agents have been used to try to detect the lymph nodes draining penile cancers. Unfortunately, all suffer from various problems, such as exposing the patient to radioactivity, and none have emerged as a standard of care.

30

[0014] It will be appreciated that penile tumors can spread in two planes: both laterally along the surface of the penis and vertically, into the penis. Thus, a tumor can be considered to have both edges, defining the lateral borders of the tumor, and a base, defining the depth to which the tumor has invaded into the tissue and structures of the penis. Surprisingly, it has  
5 now been discovered that the lymph nodes draining the cancer can be localized and visualized by injecting the edges or base of the tumor, or preferably, both, with a non-toxic, fluorescent dye. Thus, if the tumor is located on the glans of the penis, the injections will be in the glans, while a tumor in the prepuce (more familiarly known as the foreskin), the injections will be into the prepuce. For tumors that have invaded into one or both of the  
10 corpus cavernosum, injections are made into the base of the tumor in the affected corpus cavernosum. (As persons of skill are aware, "corpus cavernosum" is the singular form and "corpora cavernosa" is the plural form. For convenience, the corpora cavernosa will sometimes be referred to herein as the "cavernous bodies." Also for convenience of reference, the ability to locate and visualize nodes can be referred to as "localizing" the  
15 nodes.)

[0015] The dye injections are typically about 30 to 300  $\mu\text{l}$  each, more preferably about 50 to about 200  $\mu\text{l}$ , still more preferably about 60 to about 175  $\mu\text{l}$ , more preferably about 75 to about 150  $\mu\text{l}$ , more preferably about 90 to about 125  $\mu\text{l}$  each, more preferably about 100  $\mu\text{l}$ , and most preferably 100  $\mu\text{l}$  each, with "about" in this context meaning plus or minus 15  $\mu\text{l}$ .  
20 For a small tumor, as few as two shots around the edges or base of the tumor will be sufficient. Larger tumors will typically take 5 shots dispersed around the edges and base. Larger tumors with deeper invasion into the tissues and cavernous bodies could require up to 10 injections. Urologic surgeons are considered to be familiar with the criteria for staging penile cancers, which are based in part on the extent to which the tumor has invaded the  
25 tissue; selecting a suitable number of injections for tumors of different sizes is considered to be within the skill of the practitioner.

[0016] In studies in an animal model, injection of an exemplar fluorescent dye, indocyanine green (ICG) resulted in the ability to visualize the lymph nodes in as little as 10 minutes after injection. Thus, if desired, dye injections can be made as soon as the patient is in the  
30 operating room and under anesthesia. To minimize the duration of use of the operating room and surgical team, however, the injections will more typically be given pre-operatively. Patients are, typically prepared for penile cancer surgery in a pre-anesthesia room an hour or two before the surgery, during which time they are given mild sedation or a calming

medication. Conveniently, the dye injections are made after the sedative has taken effect to reduce the patient's discomfort at receiving small penile injections.

[0017] In animal studies, lymph nodes could be seen through the body wall for days after injection; however, in the context of detecting and visualizing sentinel nodes, periods as long  
5 as 24 hours may permit the dye to disperse to more distal lymph nodes. Thus, to facilitate identifying the sentinel nodes rather than more distal lymph nodes to which the dye may disperse, it is preferable to administer the dye 12 hours or less before the surgical operation, with 11, 10, 9, 8, 7, 6, 5, 4, 3, and 2 hours being successively more preferred. In still more preferred embodiments, the dye is administered about 1 to 2 hours before the operation, with  
10 "about" in this context meaning one-half hour on either side of the designated time. Most preferably, the dye is injected about 1 hour before the operation, with "about" in this context meaning plus or minus 15 minutes, permitting the dye to reach the sentinel nodes while minimizing the dispersion to more distal nodes.

[0018] Figure 1 shows fluorescence in a rat injected in the cavernous bodies with ICG.  
15 Arrows point to the lymphatic channels and to the lymph nodes. More than one sentinel nodes were visualized in two rats. No fluorescence was seen in control animals injected with saline. Intraoperative observations confirmed the preoperative localization of the inguinal nodes. All lymph nodes were confirmed by conventional histological review. Figure 2 shows an intraoperative image of left inguinal lymph nodes following injection of ICG into  
20 the cavernous bodies.

[0019] It is understood that fluorescent dyes have a particular excitation wavelength which causes the dye to fluoresce and emit light of a particular emission wavelength. As persons of skill are aware, there is a considerable literature on the characteristics of different dyes, including their excitation wavelength and emission wavelength.

[0020] The methods described herein are suitable for use in mammals. Examples of mammals for which the techniques can be used include, but are not limited to, non-human primates, dogs, cats, sheep, cows, pigs, horses, and rabbits. The methods are particularly useful in visualizing lymph nodes in humans, and particularly the lymph nodes draining the penis in humans.



### **Penile anatomy**

[0021] It is assumed that urologic surgeons and other persons of skill are well familiar with the anatomy of the penis, the prostate, and the surrounding areas, and that no detailed  
5 discussion is needed here. For purposes of the present discussion, it is noted that the penis can be thought of as comprising three cylinders. Two, the corpora cavernosa, are disposed on either side of the penis, and make up the bulk of the penis. The third, the corpus spongiosum, which contains the urethra, is disposed in the middle of the penis, in a cleft between the undersides of the corpora cavernosa. A "deep artery" runs down the center of each corpus  
10 cavernosum and provides blood to sinusoidal spaces in the respective corpus. The end of the penis distal to the body ends in the glans penis which, in uncircumcised males, is protected by the prepuce.

### **Penile Cancer**

[0022] As noted in the Background, the National Cancer Institute (NCI) indicates that,  
15 when diagnosed early (stage 0, stage I, and stage II), penile cancer is highly curable, but curability decreases sharply for stage III and stage IV. Criteria for staging penile cancer are known in the art. The most common system is the "TNM" (for: "tumor, node, metastasis") system of the American Joint Committee on Cancer, set forth at, e.g., Penis: American Joint Committee on Cancer, AJCC Cancer Staging Manual, 6th Ed., Springer, NY NY, 2002, pp.  
20 302-8. The NCI website notes with regard to stage 0 cancer, that carcinoma *in situ* of the penis is referred to as erythroplasia of Queyrat when it occurs on the glans, and Bowen's disease when it occurs on the penile shaft. These precursor lesions progress to invasive squamous cell carcinoma in 5% to 15% of cases. The NCI website notes that surgical  
25 excision can result in scarring, deformity, and impaired function, and that Mohs micrographic surgery, which involves the excision of successive horizontal layers of tissue with microscopic examination of each layer in frozen section, has been developed for use in patients with *in situ* and invasive penile cancers. See, e.g., Mohs et al., *J. Urol.* 133(6): 961-6 (1985).

[0023] With regard to therapeutic options for stage 1 penile cancer, the NCI website states  
30 that, for lesions limited to the foreskin, wide local excision with circumcision may be adequate therapy for control. For infiltrating tumors of the glans, with or without involvement of the adjacent skin, it states that the choice of therapy is dictated by tumor size,

extent of infiltration, and degree of tumor destruction of normal tissue. It further states that equivalent therapeutic options include: penile amputation, radiation therapy (i.e., external-beam radiation therapy and brachytherapy), and microscopically controlled surgery. It indicates that, because of the high incidence of microscopic node metastases, elective  
5 adjunctive inguinal dissection of clinically uninvolved (negative) lymph nodes in conjunction with amputation is often used for patients with poorly differentiated tumors.

Lymphadenectomy, however, can carry substantial morbidity, such as infection, skin necrosis, wound breakdown, chronic edema, and a low, but finite, mortality rate. The NCI indicates that the impact of prophylactic lymphadenectomy on survival is not known.

10 **[0024]** The NCI states that stage II penile cancer is most frequently managed by penile amputation for local control. Whether the amputation is partial, total, or radical will depend on the extent and location of the neoplasm. External beam radiation therapy and brachytherapy with surgical salvage are alternative approaches.

**[0025]** The NCI site further states that inguinal adenopathy in patients with stage III penile  
15 cancer is common but may be the result of infection rather than neoplasm. The website further states that, if palpable enlarged lymph nodes exist 3 or more weeks after removal of the infected primary lesion and completion of a course of antibiotic therapy, bilateral inguinal lymph node dissection should be performed. The methods of the present invention can be performed to assist in dissection of the nodes. Since, in this case, the primary lesion has been  
20 removed, the injections are of course made into the cavernous bodies. In cases of proven regional inguinal lymph node metastasis without evidence of distant spread, bilateral ilioinguinal dissection is the treatment of choice. Clinically evident regional lymph node metastasis without evidence of distant spread is an indication for bilateral ilioinguinal lymph node dissection after penile amputation. Radiation therapy may be considered as an  
25 alternative to lymph node dissection in patients who are not surgical candidates. Postoperative radiation therapy may decrease incidence of inguinal recurrences.

**[0026]** With respect to stage IV disease, the NCI notes that there is no curative standard treatment. Therapy is directed at palliation, which may be achieved either with surgery or radiation therapy. The standard treatment options include palliative surgery for control of the  
30 local penile lesion and palliative radiation therapy for the primary tumor, regional adenopathy, and bone metastases.

## Instrumentation

[0027] Conveniently, the device used for visualization comprises both a laser and a camera. For convenience of reference, the discussion below refers to the exemplar dye ICG. Persons  
5 of skill will recognize that the other dyes mentioned herein as suitable for use in the inventive methods and procedures could be substituted for ICG, with the light source selected or adjusted to provide illumination optimized for the excitation frequency suitable for the particular dye chosen and the device for capturing the light emitted by the dye being selected or adjusted to be able to receive light of the appropriate frequency. For use with ICG, the  
10 laser conveniently consists of a laser diode providing a maximum of 3W output at 806 nm. For other dyes, the laser diode is selected to provide a light with a wavelength at an excitation frequency appropriate for the dye selected.

[0028] The laser output is decollimated (i.e. optics are used to spread out the laser light from a tight beam) to provide even illumination over a field of view, for example, 7.6 cm by  
15 7.6 cm at a working distance of 30 cm. The imaging system typically has a camera containing a charge-coupled device ("CCD") or a complementary symmetry metal oxide semiconductor ("CMOS") image sensor sensitive into the near infrared spectrum and, for use with ICG, is equipped with an 815 nm edge filter. In some embodiments, the laser or camera or both, are supported by an articulated arm connected to a wheeled base. This allows the  
20 imaging head to be moved into close proximity to the surgical table and for vertical movement of the head to attain an appropriate focal distance above the area of interest. The imaging head and extension arm that protrudes over the surgical field are typically covered with an optically transparent sterile drape. The laser can conveniently be activated by means of a computer command or by foot pedal. Laser/camera devices suitable for intra-operative  
25 imaging are commercially available. In some preferred embodiments, the laser/camera device is a SPY® Intra-operative Imaging System, a HELIOS® Imaging System, or a LUNA® Imaging System (all by Novadaq Technologies, Inc., Mississauga, Ontario, Canada).

[0029] In some embodiments, an instrument having an optical configuration similar to a  
30 fluorescence microscope may be used, in which a dichroic mirror is used to split the paths of the illumination (the excitation light). The excitation light reflects off the surface of the dichroic mirror into the objective, while the fluorescence emission passes through the

dichroic mirror to the eyepiece or is converted into a signal to be presented on a screen. The instrument may further have an excitation filter or an emission filter, or both, to select the wavelengths appropriate for each function. Conveniently, the filters are interference filters, which block transmission of frequencies out of their bandpass.

5 [0030] For visualizing the lymph nodes and channels in the area of interest, the ICG is administered by injection into the cavernous bodies, preferably into the crura, permitting the dye to be transported through the lymphatic channels serving the area to the sentinel node or nodes. Following an interval sufficient for the dye to be transported through the channels to the nodes, a 806 nm excitation light causes the dye to fluoresce, emitting light at 830 nm.  
10 The emitted light can then be imaged directly or, preferably, is captured using an imaging system. As noted, the capture system is typically a video camera containing a CCD or CMOS image sensor. The capture system feeds the image to a monitor so that the surgeon can visualize the fluorescence of the dye in the lymph nodes in the area of interest in real time. Filters limit the light detected to a range appropriate for the selected fluorescence  
15 wavelengths. Optionally, the camera is also attached to a computer and the image is saved, which not only permits documentation of the extent to which the tumor or tumors, but also can be used for training urologic surgeons, nurses, and other medical staff. Typically, the time required for positioning the device is 2 minutes, while the total time that the vessels are illuminated with laser light is 30 seconds.

20 [0031] The methods described herein are suitable for use in mammals. Examples of suitable mammals include, but are not limited to, humans, non-human primates, dogs, cats, sheep, cows, pigs, horses, mice, rats, rabbits, and guinea pigs. Use in humans is preferred, and particularly in humans, is preferred.

## 25 **Dyes for imaging**

[0032] As persons of skill are aware, fluorescent dyes have a particular excitation wavelength which causes the dye to fluoresce and emit light of a particular emission wavelength. Persons of skill will appreciate that a considerable literature is available in the art on the characteristics of different dyes, including their excitation wavelength and emission  
30 wavelength. This literature is well known, and will not be set forth in detail herein.

[0033] The dye is imaged by exciting it with a light that has an excitation wavelength appropriate for the particular dye used. Persons of skill are aware that a variety of dyes exist,

and that each dye has an excitation wavelength and an emission wavelength. Some dyes, for example, fluoresce under ultraviolet ("UC") illumination while others fluoresce under incandescent illumination. The literature on the use of fluorescent dyes and probes in biological assays includes, for example, Dewey, T.G., *Ed.*, *Biophysical and Biochemical Aspects of Fluorescence Spectroscopy*, Plenum Publishing (1991), Guilbault, G.G., *Ed.*, *Practical Fluorescence*, Second Edition, Marcel Dekker (1990), Lakowicz, J.R., *Ed.*, *Topics in Fluorescence Spectroscopy: Techniques* (Volume 1, 1991); *Principles* (Volume 2, 1991); *Biochemical Applications* (Volume 3, 1992); *Probe Design and Chemical Sensing* (Volume 4, 1994); *Nonlinear and Two-Photon Induced Fluorescence* (Volume 5, 1997); *Protein Fluorescence* (Volume 6, 2000); *DNA Technology* (Volume 7, 2003); Plenum Publishing, and Lakowicz, J.R., *Principles of Fluorescence Spectroscopy*, Second Edition, Plenum Publishing (1999) and W.T. Mason, ed., *Fluorescent and Luminescent Probes for Biological Activity. A Practical Guide to Technology for Quantitative Real-Time Analysis*, Academic Press (Second Ed., 1999).

**[0034]** Preferably, the dye selected is one that has low toxicity and has excitation and emission peaks within the "optical window" of tissue, where absorption due to endogenous chromophores is low. Preferred fluorescent dyes suitable for use in the methods of the invention are non-toxic dyes which fluoresce when exposed to radiant energy, e.g. light. Preferably, the dyes are near infrared fluorochromes, or "NIRF" that emit light in the near infra red spectrum. Near infrared light can penetrate tissue to a depth of several millimeters to a few centimeters. In some embodiments, the dye is a tricarbo-cyanine dye, and in particularly preferred embodiments, is ICG. In other embodiments the dye is selected from fluorescein isothiocyanate, rhodamine, phycoerythrin, phycocyanin, allophycocyanin, o-phthaldehyde, fluorescamine, Rose Bengal, trypan blue, and fluoro-gold. The dyes may be mixed or combined. In some embodiments, dye analogs may be used. A "dye analog" is a dye that has been chemically modified, but still retains its ability to fluoresce when exposed to radiant energy of an appropriate wavelength.

**[0035]** ICG, Fast Blue and Fluorogold have all been used in mammals with low evidence of toxicity and are preferred. As noted, ICG is particularly preferred both because it has low toxicity and because it has been approved by the Food and Drug Administration for several diagnostic purposes in humans. Further, its absorption (excitation) and emission peaks (805 and 835 nm, respectively) lie within the "optical window" of tissue. ICG is commercially available from, for example, Akorn, Inc. (Buffalo Grove, IL), which sells it under the name

IC-GREEN™. After intravenous injection, ICG is bound within 1 to 2 seconds, mainly to globulins (1-lipoproteins), and remains intravascular, with normal vascular permeability. ICG is not metabolized in the body and is excreted exclusively by the liver, with a plasma half-life of 3 to 4 minutes. It is not reabsorbed from the intestine and does not undergo enterohepatic recirculation. The recommended dose for ICG video angiography is 0.2 to 0.5 mg/kg; the maximum daily dose should not exceed 5 mg/kg.

**[0036]** For intraoperatively visualizing the lymph nodes and channels, the surgical field, or the portion of the surgical field in which imaging is desired, is illuminated with a light of the excitation wavelength or wavelengths suitable for the dye or dyes used. Since the channels are thin and the nodes are small (accounting in part for the difficulty in discerning them with the unaided eye), ambient light may need to be dimmed to permit the fluorescence to be seen. Observation will typically also require magnification. Where the excitation wavelength is outside of the visible range (where, for example, the excitation wavelength is in the ultraviolet or near infrared range), the light source may be designed to permit switching or "togglng" between the excitation wavelength and visible light. This permits the practitioner to note the position of the node or nodes using the fluorescent property in relation to the rest of the surgical field and surrounding (but non-fluorescent) structures.

**[0037]** In some embodiments, an instrument having an optical configuration similar to a fluorescence microscope may be used, in which a dichroic mirror is used to split the paths of the illumination (the excitation light). The excitation light reflects off the surface of the dichroic mirror into the objective, while the fluorescence emission passes through the dichroic mirror to the eyepiece or is converted into a signal to be presented on a screen. The instrument may further have an excitation filter or an emission filter, or both, to select the wavelengths appropriate for each function. Conveniently, the filters are interference filters, which block transmission of frequencies out of their bandpass.

**[0038]** The dye is typically administered by an injection into one or both of the corpora cavernosa. Typically, the dye will be administered some hours preoperatively, to permit the dye to be transported to the nodes in the area of interest prior to commencing the surgical operation.

**[0039]** Conveniently, the dye may be administered in the patient's room. Typically, the dye is administered sufficiently before the intended surgery to permit the dye to flow to the sentinel nodes draining the tumor area, but not so long before the surgery that the dye has

been cleared from the nodes. Since the nodes could be detected through the body wall of the animals from 2 hours to 7 days after injection, it appears that the dye can be administered at the convenience of the patient and the practitioner from 2 hours up to a week before the intended surgery. Typically, however, a patient presenting with penile cancer will be injected  
5 with the dye no more than a few days before surgery is contemplated, since delay in performing the surgery will rarely be to the patient's benefit. Typically, therefore, the dye is administered at least about 2 hours but not more than 72 hours before the intended surgery. In some embodiments, the dye is administered at least about 2 hours but not more than 48 hours before the intended surgery. In other embodiments, the dye is administered at least  
10 about 2 hours but not more than 36 hours before the intended surgery. In preferred embodiments, the dye is administered between about 2 hours to 24 hours before the intended surgery. In still preferred embodiments, the dye is administered between about 2 hours to about 14 hours before the intended surgery, with "about" meaning a half hour on either side. Whether the patient has been injected too recently to provide adequate time for the dye to  
15 drain to the lymph nodes (for example, a half hour after injection, the dye would not yet be expected to have drained sufficiently to the nodes for optimal detection) can be readily determined pre-operatively by simply illuminating the groin with near infrared illumination under conditions permitting detecting any light emitted by the dye. If fluorescence is not sufficient to permit visualization of the nodes in the groin, a technician can simply  
20 reilluminate the area at half hour intervals or such other intervals as may be convenient until sufficient dye has drained to the sentinel lymph nodes to permit ready visualization.

[0040] The maximum daily dosage of ICG for adults is 2 mg/kg. There is no data available describing the signs, symptoms, or laboratory findings accompanying an overdose of ICG. The LD<sub>50</sub> after IV administration ranges between 60 and 80 mg/kg in mice, 50 and 70 mg/kg  
25 in rats, and 50 to 80 mg/kg in rabbits.

## EXAMPLES

### Example 1

[0041] Intraoperative video angiography is performed with a laser-fluorescence imaging  
30 device (Novadaq Technologies, Inc., Mississauga, Ontario, Canada) consisting of a near infrared (NIR) laser light source and a NIR-sensitive digital camcorder. For measurements, the unit is positioned 30 to 40 cm from the area of interest. ICG, dissolved in water, is then

injected as a bolus. The NIR light emitted by the laser light source induces ICG fluorescence. The fluorescence is recorded by a digital video camera, with optical filtering to block ambient and laser light so that, when desired, only ICG fluorescence is captured. Images can be observed on screen in real time (25-30 images/sec). The images can be reviewed and stored  
5 on the digital video camera or transferred to a computer or to storage media.

### Example 2

[0042] Sprague-Dawley rats, 60 to 100 days old, weighing 275-325 grams are used. All animals are anesthetized using intraperitoneal injection of Ketamine/Xylazine (40-80 mg/kg  
10 and 5/10 mg/kg, respectively) or isoflurane. No pre-anesthetic medications are used. When appropriate depth of anesthesia is reached, positioning of the animal takes place. All animals are fastened to a padded and heated restraint device in the supine position using gauze knots to fix all four extremities. Depth of anesthesia, regularity of respirations, and heart beat palpation are repeatedly checked. A pulse oximeter may be used to monitor the animal.  
15 Placebo (distilled water) or fluorochromes, ICG or Fluorogold, is administered by intrapenile, sub-albugineal injection of 25 $\mu$ l of ICG diluted in 100  $\mu$ l of water for injection, per cavernous body.

[0043] Surgery/Procedure starts after appropriate preparation of surgical field by Povidone-Iodine scrub, 70% Isopropyl Alcohol and Povidone-Iodine solution. The surgical field  
20 includes the genital area, lower abdomen and perineum. The penis is squeezed out from the prepuce, then stretched using finger grip of the glans until maximally stretched; a clamp used for atraumatic clamping in neurosurgical operation on brain aneurysms is then placed at the root of the penis. This allows blood to pool inside the cavernous bodies, producing an erection and permitting easier application of a 27 Gauge butterfly needle to both sub-  
25 albugineal spaces. Adequate placement is assured when blood is easily aspirated. 0.5 mg/kg of ICG and 1mg/kg of Fluorogold diluted in distilled water to total volume of 50  $\mu$ l is injected, 25 $\mu$ l per cavernous body. A placebo group is injected using 25 $\mu$ l of distilled water per cavernous body. Animals in all groups have an exploratory laparotomy through midline  
30 incisions are made from umbilicus to pubis. Bowels and testicles after their release from scrotal attachments are packed back to upper abdomen. For better visualization of the pelvic structures, surgical loupes with 3.8 X magnification are used. After release of the clamps, the



27 Gauge needles are removed, but slight finger pressure at the injection sites is maintained for 3-5 minutes to prevent extravasation. Buprenorphine (0.01-0.05 mg/kg) is administered intraoperatively and then as needed to control pain.

[0044] Post-procedurally, optimal recovery is routinely performed in all animals: animals are kept warm using warming packs, pads and lamps, the animals are placed on a paper towel, and are rotated from side to side every 15 minutes until they are able to maintain sternal recumbence. 3-4ml of Lactated Ringer solution, warmed to 37°C, is administered subcutaneously and unilaterally in the flank region, preventing postoperative dehydration of the animal. Animals are attended at all times during postoperative recovery. The animals are then returned to their home cages, and hydration is assessed on a daily basis. Analgesia is used for all animals for postoperative pain. Animals are checked for signs of pain every 6 hours during first 24 hours post-surgery and then every 12 hours until euthanasia. Signs of acute pain are guarding (protecting the painful area), vocalization, especially when the animal moves or the painful area is touched, licking, biting, scratching or shaking a particular area, pacing, lack of mobility as seen with joint, colic or gut pain or an unusual gait posture during movement, failure to groom, causing an unkempt appearance, abnormal resting postures, loss of appetite or reduction in water consumption, and changes in behavior or signs of aggression.

[0045] To perform harvesting of lymph nodes, the rats undergo a second surgery (non-survival) and postmortem harvesting at chosen timepoints after fluorochrome injection.

[0046] Anesthesia identical to the first procedure is administered and then appropriate skin preparation for surgery is performed. The same level of incision is used in second surgery/harvesting procedure. The bladder and prostate are exposed as in the first surgery. The penis is denuded of skin and the prepuce circumcised. The animal is euthanized by cardiac exsanguination. Death of the animal is confirmed using pulse oximeter and observation of complete absence of heart contractions.

### Example 3

[0047] Twenty two 22 male Sprague-Dawley rats received penile intracavernous ICG injections (20 µl of 0.25 mg/ml). From 2 hours to 7 days later, near infrared fluorescence (NIRF) imaging was performed both before and during dissection. Control rats received comparable saline injections at several time points. A Novadaq intraoperative NIRF imaging

system (SPY®) was used for macroscopic fluorescence imaging and an Olympus NIRF microscope IX 70 (Olympus America, Inc., Center Valley, PA) was used for histology. All animals were anesthetized and shaved before imaging. All visualized nodes were sent for NIR microscopy and haematoxylin and eosin (H&E) staining for histological examination.

#### 5 **Example 4**

[0048] Inguinal lymph node NIRF was detected through the body wall from 2 hours to 7 days after ICG injection (Fig. 1). More than one pair of sentinel lymph nodes were visualized in 2 rats. No fluorescence was seen in controls. Intraoperative observations confirmed preoperative localization of all inguinal nodes (Fig. 2). Inguinal and iliac sentinel lymph nodes were clearly visualized with NIRF, and were difficult to visualize otherwise. Lymphatic channels were seen leading to sentinel lymph nodes at 6, 12 and 24 hours (Fig. 1). Lymphatic channels leading to the sentinel lymph nodes were seen in animals examined at 6, 12, and 24 hours post-injection of ICG. (Fig. 1). All lymph nodes were confirmed by NIR microscopy and by conventional histology. Thus, NIR fluorescence using ICG facilitates both pre- and intraoperative identification of the first site of penile lymphatic drainage. The methods of the invention should therefore improve the accuracy of surgical staging in patients with penile carcinomas.

[0049] It is understood that the examples and embodiments described herein are for illustrative purposes only and that various modifications or changes in light thereof will be suggested to persons skilled in the art and are to be included within the spirit and purview of this application and scope of the appended claims. All publications, patents, and patent applications cited herein are hereby incorporated by reference in their entirety for all purposes.

WHAT IS CLAIMED IS:

- 1                   1.       A method of localizing before or during a surgical operation a lymph  
2 node draining a penile tumor having edges and a base, in a subject, comprising:  
3                   a) about 10 minutes to 24 hours prior to said surgical operation, injecting the  
4 edges or the base of said tumor of said subject with a dye which fluoresces at an emission  
5 wavelength when said dye is contacted with an excitation wavelength;  
6                   b) exposing said lymph node before or during said operation to illumination  
7 comprising said excitation wavelength, thereby causing said fluorescent dye to fluoresce;  
8 and,  
9                   c) detecting the fluorescence of said dye,  
10 thereby localizing said lymph node before or during said surgical operation.
- 1                   2.       A method of claim 1, wherein said lymph node is a sentinel lymph  
2 node.
- 1                   3.       A method of claim 1, wherein said dye is injected into the edges of  
2 said tumor.
- 1                   4.       A method of claim 1, wherein said dye is injected into the base of said  
2 tumor.
- 1                   5.       A method of claim 1, wherein said lymph node is visualized on a  
2 image display.
- 1                   6.       A method of claim 1, wherein said exposing of said lymph node to  
2 excitation wavelength is by a laparoscopic instrument.
- 1                   7.       A method of claim 1 wherein said dye is a dye which fluoresces when  
2 exposed to near infrared light.
- 1                   8.       A method of claim 1, wherein said dye is a tricarboyanine dye or an  
2 analog thereof.
- 1                   9.       A method of claim 8, wherein the tricarboyanine dye is indocyanine  
2 green.
- 1                   10.      A method of claim 1, wherein the subject is a human.

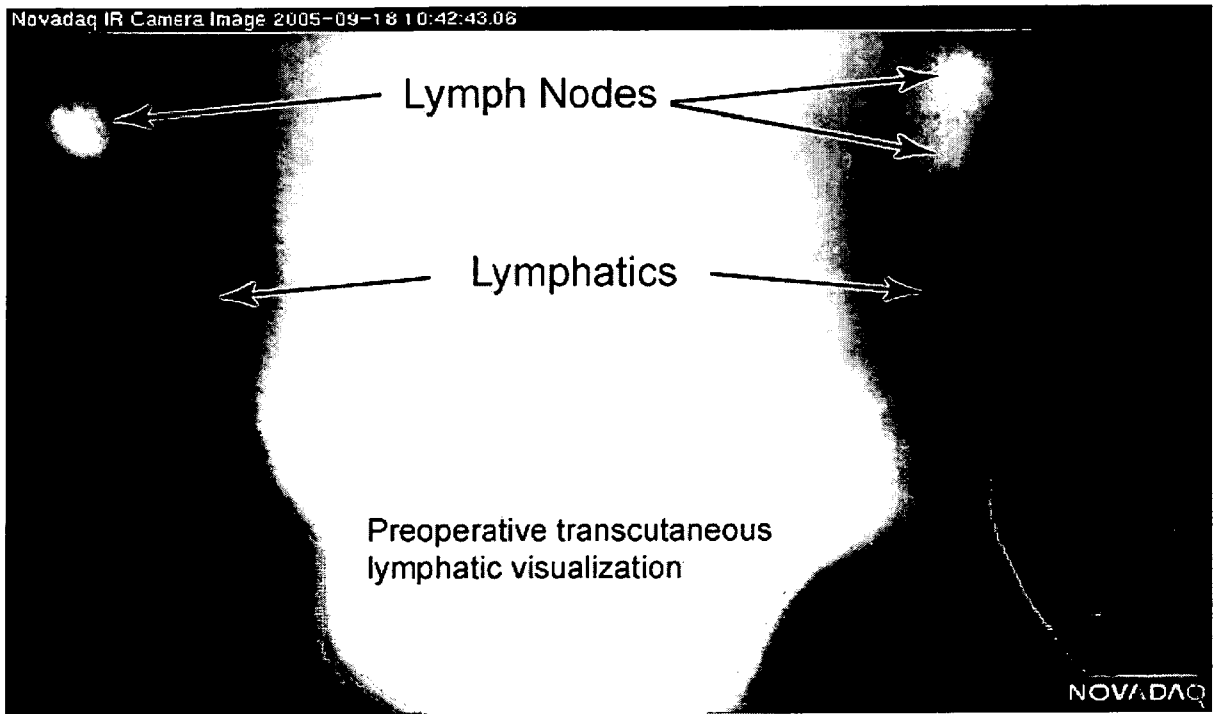
1                    11.    A method of claim 1, wherein said dye is injected between about 10  
2 minutes and 12 hours before said surgical operation.

1                    12.    A method of claim 1, wherein said dye is injected between about 1  
2 hour and about 6 hours before said surgical operation.

1                    13.    A method of claim 1, wherein said dye is injected between about 1  
2 hour and about 2 hours before said surgical operation.


1                    14.    A method of claim 1, wherein said steps (b) and (c) are performed  
2 during said operation.

1                    15.    A method of claim 1, wherein said operation is a laparoscopic  
2 operation.



**FIG. 1**

# Intraoperative image of left inguinal lymph nodes



**FIG. 2**