



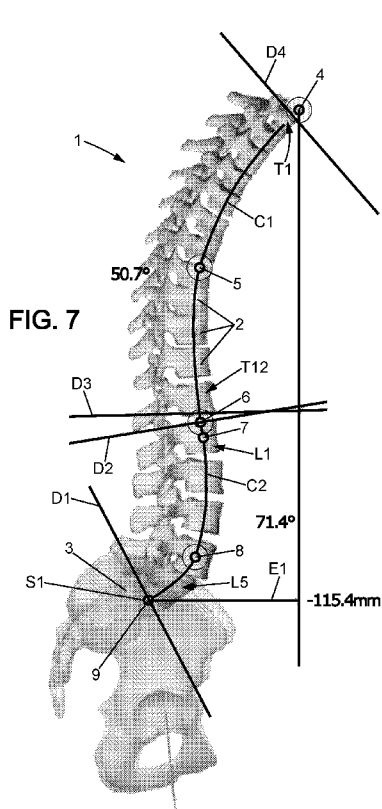
- (51) International Patent Classification:
A61B 34/10 (2016.01) *A61B 17/70* (2006.01)
- (21) International Application Number:
PCT/IB2015/002497
- (22) International Filing Date:
19 November 2015 (19.11.2015)
- (25) Filing Language: English
- (26) Publication Language: English
- (71) Applicant: EOS IMAGING [FR/FR]; 10, rue Mercoeur, 75011 Paris (FR).
- (72) Inventors: HOBEIKA, Joe; 18D rue des Jardins, 25000 Besancon (FR). VANCURA, Lukas; 21 Passage Gatbois, 75012 Paris (FR).
- (74) Agents: CABINET PLASSERAUD et al.; 66, rue de la Chaussée d'Antin, 75440 Paris Cedex 09 (FR).
- (81) Designated States (unless otherwise indicated, for every kind of national protection available): AE, AG, AL, AM,

AO, AT, AU, AZ, BA, BB, BG, BH, BN, BR, BW, BY, BZ, CA, CH, CL, CN, CO, CR, CU, CZ, DE, DK, DM, DO, DZ, EC, EE, EG, ES, FI, GB, GD, GE, GH, GM, GT, HN, HR, HU, ID, IL, IN, IR, IS, JP, KE, KG, KN, KP, KR, KZ, LA, LC, LK, LR, LS, LU, LY, MA, MD, ME, MG, MK, MN, MW, MX, MY, MZ, NA, NG, NI, NO, NZ, OM, PA, PE, PG, PH, PL, PT, QA, RO, RS, RU, RW, SA, SC, SD, SE, SG, SK, SL, SM, ST, SV, SY, TH, TJ, TM, TN, TR, TT, TZ, UA, UG, US, UZ, VC, VN, ZA, ZM, ZW.

- (84) Designated States (unless otherwise indicated, for every kind of regional protection available): ARIPO (BW, GH, GM, KE, LR, LS, MW, MZ, NA, RW, SD, SL, ST, SZ, TZ, UG, ZM, ZW), Eurasian (AM, AZ, BY, KG, KZ, RU, TJ, TM), European (AL, AT, BE, BG, CH, CY, CZ, DE, DK, EE, ES, FI, FR, GB, GR, HR, HU, IE, IS, IT, LT, LU, LV, MC, MK, MT, NL, NO, PL, PT, RO, RS, SE, SI, SK, SM, TR), OAPI (BF, BJ, CF, CG, CI, CM, GA, GN, GQ, GW, KM, ML, MR, NE, SN, TD, TG).

Published:
— with international search report (Art. 21(3))

(54) Title: METHOD OF PREOPERATIVE PLANNING TO CORRECT SPINE MISALIGNMENT OF A PATIENT



(57) Abstract: This invention relates to a method of preoperative planning to correct spine (1) misalignment of a patient, comprising a step of making a translation and a rotation, in a sagittal plane, of each vertebra (2) of a set of several cervical and/or thoracic (T1-T12) and/or lumbar (L1-L5) imaged spine vertebrae (2), so that said set of imaged vertebrae (2) presents afterwards, in the sagittal plane, the same cervical lordosis and/or the same thoracic kyphosis and/or the same lumbar lordosis as a model adapted for said patient, wherein it also comprises, before said step of making said translation and said rotation in a sagittal plane: a step of making a translation and a rotation, in a coronal plane, of each vertebra (2) of said set of several cervical and/or thoracic (T1-T12) and/or lumbar (L1-L5) imaged spine vertebrae (2), so that said set of imaged vertebrae (2) becomes straight in said coronal plane, and of making a rotation, in an axial plane, of each vertebra (2) of said set of several cervical and/or thoracic (T1-T12) and/or lumbar (L1-L5) imaged spine vertebrae (2), so that said set of imaged vertebrae (2) becomes axially aligned.

WO 2017/085529 A1

**METHOD OF PREOPERATIVE PLANNING TO CORRECT SPINE
MISALIGNMENT OF A PATIENT**

5 **FIELD OF THE INVENTION**

The invention relates to a method of preoperative planning to correct spine misalignment of a patient and to the associated pre-shaped or pre-twisted rod, to be integrated within a patient body to support a patient spine,
10 which has been pre-shaped or pre-twisted according to position and orientation of a set of imaged vertebrae after a step of making a translation and a rotation in a sagittal plane performed during such a method of preoperative planning to correct spine misalignment of a patient.

15 **BACKGROUND OF THE INVENTION**

According to a prior art, it is known a method of preoperative planning to correct spine misalignment of a patient based on a step of making a translation and a rotation, in a sagittal plane, of each vertebra of a set of several cervical and/or thoracic and/or lumbar imaged spine vertebrae,
20 so that said set of imaged vertebrae presents afterwards, in the sagittal plane, the same cervical lordosis and/or the same thoracic kyphosis and/or the same lumbar lordosis as a model adapted for said patient.

Unfortunately, in this prior art, the translation and rotation performed
25 in the sagittal plane lead to an associated pre-twisted rod to be integrated within a patient body to support a patient spine, which has been pre-twisted according to position and orientation of a set of imaged vertebrae after a step of making a translation and a rotation in a sagittal plane performed during such a method of preoperative planning to correct spine
30 misalignment of a patient which lacks precision as to its length and as to its curvature location.

Indeed, the length of the rod is not the correct one, and if cervical lordosis and/or thoracic kyphosis and/or lumbar lordosis present correct curvatures, these curvatures are not located at the right place, specific points of these curvatures, like for example maximum points, minimum points, inflexion points, are shifted and located at the wrong parts of the vertebrae if not at the wrong vertebrae.

Therefore, during subsequent operative treatment, the surgeon will need re-twisting empirically, maybe in an iterative way, this pre-twisted rod so as to fit it correctly to the patient.

10

SUMMARY OF THE INVENTION

The object of the present invention is to alleviate at least partly the above mentioned drawbacks.

More particularly, the invention aims to provide for a more precise method of preoperative planning to correct spine misalignment of a patient leading to an associated pre-twisted rod presenting a more precise length and/or a more precise location of at least one of the curvatures of cervical lordosis and/or thoracic kyphosis and/or lumbar lordosis, preferably presenting a more precise length and a more precise location of at least of the curvatures of all imaged and studied spine portions among cervical lordosis and/or thoracic kyphosis and/or lumbar lordosis.

20

Therefore, the invention proposes, before the step of making translation and rotation in a sagittal plane of the imaged spine vertebrae, to make a translation and a rotation, in a coronal plane, of the imaged spine vertebrae so as to make them straight in the coronal plane, and a rotation, in an axial plane, of the imaged spine vertebrae so as to make them axially aligned.

25

This way, the step of making translation and rotation in a sagittal plane of the imaged spine vertebrae can be performed on an imaged spine already corrected from scoliosis and from axial vertebrae misalignment.

30

The correct cervical lordosis and/or thoracic kyphosis and/or lumbar lordosis may then be implemented on an imaged spine presenting already a straight axis in the coronal plane and an axially aligned imaged spine in the axial plane. The obtained pre-twisted rod is then much more precise, in
5 length and/or in curvature location, having been manufactured or deformed according to a completely correctly amended imaged spine and not according to a partly correctly amended imaged spine as in prior art.

This object is achieved with a method of preoperative planning to correct spine misalignment of a patient, comprising a step of making a
10 translation and a rotation, in a sagittal plane, of each vertebra of a set of several cervical and/or thoracic and/or lumbar imaged spine vertebrae, so that said set of imaged vertebrae presents afterwards, in the sagittal plane, the same cervical lordosis and/or the same thoracic kyphosis and/or the same lumbar lordosis as a model adapted for said patient, wherein it also
15 comprises, before said step of making said translation and said rotation in a sagittal plane: a step of making a translation and a rotation, in a coronal plane, of each vertebra of said set of several cervical and/or thoracic and/or lumbar imaged spine vertebrae, so that said set of imaged vertebrae becomes straight in said coronal plane, and of making a rotation, in an axial
20 plane, of each vertebra of said set of several cervical and/or thoracic and/or lumbar imaged spine vertebrae, so that said set of imaged vertebrae becomes axially aligned.

Making a translation and a rotation, in a coronal plane, of each vertebra, and making a rotation, in an axial plane, of each vertebra, may be
25 performed either successively in two successive steps or simultaneously within the same step. When performed successively in two successive steps, the step of making a translation and a rotation, in a coronal plane, of each vertebra, may be performed before the step of making a rotation, in an axial plane, of each vertebra. When performed successively in two successive
30 steps, the step of making a translation and a rotation, in an axial plane, of each vertebra, may be performed before the step of making a rotation, in a

coronal plane, of each vertebra. Preferably, the translation in the coronal plan is performed with the first rotation, either the one in coronal plan or the one in axial plan. It is also possible, although less efficient, to perform each step separately, in whatever order, one step being a translation in coronal
5 plan, one other step being a rotation in axial plan, still one other step being a rotation in axial plan.

This method of preoperative planning to correct spine misalignment of a patient, means that the steps of making translations and rotations, in different planes, of imaged vertebrae, are indeed steps of making
10 translations and rotations of elements or parts of images, on a display device as for example on a screen. Only portions of images or elements within images are translated and/or rotated on a display device during this preoperative planning; no real vertebrae of a patient spine are examined, touched or moved during this preoperative planning.

This object is also achieved with a method of preoperative planning to correct spine misalignment of a patient, comprising a step of making a translation and a rotation, in a sagittal plane, of each vertebra of a set of several thoracic and/or lumbar imaged spine vertebrae, so that said set of imaged vertebrae presents afterwards, in the sagittal plane, the same
15 thoracic kyphosis and/or the same lumbar lordosis as a model adapted for said patient, wherein it also comprises, before said step of making said translation and said rotation in a sagittal plane, successively: a step of making a translation and a rotation, in a coronal plane, of each vertebra of said set of several thoracic and/or lumbar imaged spine vertebrae, so that
20 said set of imaged vertebrae becomes straight in said coronal plane, a step of making a rotation, in an axial plane, of each vertebra of said set of several thoracic and/or lumbar imaged spine vertebrae, so that said set of imaged vertebrae becomes axially aligned.

Preferred embodiments comprise one or more of the following
30 features, which can be taken separately or together, either in partial combination or in full combination.

Preferably, the method of preoperative planning to correct spine misalignment of a patient according to the invention is applied to a set of several thoracic and several lumbar imaged spine vertebrae, so that said set of imaged vertebrae presents, in the sagittal plane, the same thoracic
5 kyphosis and the same lumbar lordosis as a model adapted for said patient. This way, the preoperative planning to correct spine misalignment of a patient and the associated pre-twisted rod will encompass a key part of patient spine, including both thoracic and lumbar vertebrae.

Preferably, the method of preoperative planning to correct spine
10 misalignment of a patient according to the invention is applied to all thoracic and all lumbar spine vertebrae, so that said patient spine presents, in the sagittal plane, the same thoracic kyphosis and the same lumbar lordosis as a model adapted for said patient. This way, the preoperative planning to correct spine misalignment of a patient and the associated pre-
15 twisted rod will encompass most of patient spine, including all thoracic and all lumbar vertebrae.

Preferably, in said step of making a translation and a rotation in said coronal plane, said translation and rotation are performed simultaneously, in said step of making a translation and a rotation in said sagittal plane, said
20 translation and rotation are performed simultaneously. This is more efficient and more realistic to perform both translation and rotation of an imaged vertebra at the same time, since afterwards during operative treatment; the surgeon will perform those vertebra moves at the same time on the real vertebrae of the patient spine to effectively correct this patient spine
25 misalignment.

Preferably, the method of preoperative planning to correct spine misalignment of a patient according to the invention also comprises, after said steps of making translations and rotations: a step of pre-twisting at least one rod, to be integrated within said patient body to support said patient
30 spine, according to position and orientation of said set of imaged vertebrae after said step of making said translation and said rotation in a sagittal plane.

Indeed, knowing position and orientation both of the misaligned starting imaged spine and of the corrected final imaged spine, the length and curvature(s) of the needed rod, to maintain corrected spine in its corrected position and orientation after such correction has been performed by the surgeon, can be deduced therefrom. Then, manufacturing or twisting a pre-manufactured rod so as to make it a pre-twisted rod can be performed according to the deduced length and curvature(s).

Preferably, in said step of pre-twisting, two rods are pre-twisted which are to be integrated respectively on both sides of said patient spine.

Preferably, the method of preoperative planning to correct spine misalignment of a patient according to the invention also comprises, after said steps of making translations and rotations: a step of editing a pattern of at least one pre-twisted rod to be integrated within said patient body to support said patient spine, according to position and orientation of said set of imaged vertebrae after said step of making said translation and said rotation in a sagittal plane. With the help of this pattern, starting from a standard rod, either the surgeon or a craftsman can make the dedicated pre-twisted rod(s) to be integrated on the patient spine and preferably on both sides of the patient spine.

Preferably, the method of preoperative planning to correct spine misalignment of patient according to the invention also comprises, after said steps of making translations and rotations: a step of calculating the length of at least one rod, to be integrated within said patient body to support said patient spine, according to position and orientation of said set of imaged vertebrae after said step of making said translation and said rotation in a sagittal plane. Calculating the exact length is very interesting, because if somewhat too short, the pre-twisted rod will not be as efficient as expected to maintain the corrected position and orientation of patient spine.

Preferably, said set of several thoracic and/or lumbar imaged spine vertebrae is a 3D spine image reconstructed from two 2D radiographic spine images, preferably from a coronal image and a sagittal image. This way,

starting from only 2D radiographic spine imaging, a performing 3D preoperative planning can be made on patient spine, leading to a performing pre-twisted rod correctly deformed in the three dimensional space.

5 Preferably, lumbar lordosis position is obtained by moving two end markers corresponding respectively to higher extreme lumbar vertebra and sacral plate and lumbar lordosis curvature is obtained by moving an intermediate marker corresponding to an intermediate lumbar vertebra located between both extreme lumbar vertebrae, and/or thoracic kyphosis position is obtained by moving two end markers corresponding respectively to both extreme thoracic vertebrae, and thoracic kyphosis curvature is obtained by moving an intermediate marker corresponding to an intermediate thoracic vertebra located between both extreme thoracic vertebrae, and/or cervical lordosis position is obtained by moving two end markers corresponding respectively to both extreme cervical vertebrae and cervical lordosis curvature is obtained by moving an intermediate marker corresponding to an intermediate cervical vertebra located between both extreme cervical vertebrae. Such techniques using two end markers and an intermediate marker lead to an optimized compromise between the precision of the curvature(s) implemented and the complexity, both in programing for the planning tool and in manipulation on display for the surgeon, rising with the number of markers. More than three markers, so two end markers and two or more intermediate markers are also possible, but this makes the system more complex for little improved precision.

25 Preferably, said model is adapted for said patient first by getting an adapted lordosis from one or more patient based parameters and second by getting an adapted kyphosis from said adapted lordosis and from one or more patient based parameters. The obtained model will be more efficient when lumbar lordosis is adapted first, and when then only, with an optimized and more or less fixed lumbar lordosis (or at most varying within a narrowly limited range), the thoracic kyphosis is adapted.

Preferably, said adapted lordosis is obtained from patient pelvic incidence and from patient population type and preferably also from patient age. This leads to an optimized compromise between the precision of the curvature(s) implemented and the complexity of calculation to get the right curvature(s).

Preferably, said adapted kyphosis is obtained from said adapted lordosis and from patient sagittal vertical axis. This leads to an optimized compromise between the precision of the curvature(s) implemented and the complexity of calculation to get the right curvature(s).

Preferably, said adapted kyphosis is obtained by varying said adapted lordosis curvature within a limited range, preferably plus or minus 10 degrees, while minimizing said patient sagittal vertical axis. This flexibility, allowing to still amend the lumbar lordosis during step of thoracic kyphosis determination after step of lumbar lordosis determination has been completed, such amendment being performed within a narrowly limited range, allows for quicker and more efficient convergence of the thoracic kyphosis than the convergence which would be obtained with a completely fixed value of lumbar lordosis.

Preferably, said spinal misalignment comes from a scoliosis and/or from a degenerative spine. Those are the diseases which can be corrected thanks to the method of preoperative planning to correct spine misalignment of a patient and/or to the associated pre-twisted rod(s), both according to embodiments of the invention.

Preferably, there is a pre-twisted rod, to be integrated within a patient body to support a patient spine, which has been pre-twisted according to position and orientation of a set of imaged vertebrae after a step of making a translation and a rotation in a sagittal plane performed during a method of preoperative planning to correct spine misalignment of a patient according to the invention. This pre-twisted rod may be used afterwards directly by the surgeon during subsequent operative treatment.

Further features and advantages of the invention will appear from the following description of embodiments of the invention, given as non-limiting examples, with reference to the accompanying drawings listed hereunder.

5

BRIEF DESCRIPTION OF THE DRAWINGS

Fig. 1 shows a frontal patient spine view, the patient suffering from scoliosis, allowing performance of a step of the method of preoperative planning according to an embodiment of the invention.

Fig. 2 shows a frontal patient spine view, the spine having been partly derotated during preoperative planning, allowing performance of a step of the method of preoperative planning according to an embodiment of the invention.

Fig. 3 shows a frontal patient spine view, where a starting phase of translation and rotation, in a coronal plane, allowing performance of a step of the method of preoperative planning according to an embodiment of the invention.

Fig. 4 shows a frontal patient spine view, where an ending phase of translation and rotation, in a coronal plane, allowing performance of a step of the method of preoperative planning according to an embodiment of the invention.

Fig. 5 shows a frontal patient spine view, where a starting phase of translation and rotation, in an axial plane, allowing performance of a step of the method of preoperative planning according to an embodiment of the invention.

Fig. 6 shows a frontal patient spine view, where an ending phase of translation and rotation, in an axial plane, allowing performance of a step of the method of preoperative planning according to an embodiment of the invention.

Fig. 7 shows a lateral patient spine view, with a high value of thoracic kyphosis, allowing performance of a step of the method of preoperative planning according to an embodiment of the invention.

5 Fig. 8 shows a lateral patient spine view, with a high value of lumbar lordosis, allowing performance of a step of the method of preoperative planning according to an embodiment of the invention.

Fig. 9 shows a lateral patient spine view, with a close to zero value of sagittal vertical axis, allowing performance of a step of the method of preoperative planning according to an embodiment of the invention.

10 Fig. 10 shows a lateral patient spine view, with a lumbar lordosis concentrated in the middle region of lumbar vertebrae, allowing performance of a step of the method of preoperative planning according to an embodiment of the invention.

15 Fig. 11 shows a lateral patient spine view, with a lumbar lordosis concentrated in the lower region of lumbar vertebrae, allowing performance of a step of the method of preoperative planning according to an embodiment of the invention.

20 Fig. 12 shows a lateral patient spine view, with a lumbar lordosis concentrated in the upper region of lumbar vertebrae, allowing performance of a step of the method of preoperative planning according to an embodiment of the invention.

25 Fig. 13 shows a lateral patient spine view, with a thoracic kyphosis concentrated in the middle region of thoracic vertebrae, allowing performance of a step of the method of preoperative planning according to an embodiment of the invention.

Fig. 14 shows a lateral patient spine view, with a thoracic kyphosis concentrated in the lower region of thoracic vertebrae, allowing performance of a step of the method of preoperative planning according to an embodiment of the invention.

30 Fig. 15 shows a lateral patient spine view, with a thoracic kyphosis concentrated in the upper region of thoracic vertebrae, allowing

performance of a step of the method of preoperative planning according to an embodiment of the invention.

DETAILED DESCRIPTION OF THE INVENTION

5

Fig. 1 shows a frontal patient spine view, the patient suffering from scoliosis, allowing performance of a step of the method of preoperative planning according to an embodiment of the invention.

A patient spine 1 comprises vertebrae 2 and is ended by pelvis 3.
10 Vertebrae 2 comprise thoracic vertebrae T1 to T12 and lumbar vertebrae L1 to L5. A sane spine 1 should appear as vertical in the coronal plan. Here, one can see that the spine 1 is heavily curved toward left of figure 1 in its upper part, corresponding to thoracic vertebrae 2, and slightly curved toward right of figure 1 in its lower part, corresponding to lumbar vertebrae
15 2. This means that represented spine 1 suffers from a disease called scoliosis. This means that represented spine 1 should be made straight in coronal plan. Therefore, imaged thoracic vertebrae T1 to T12 should be moved to the right of figure 1, whereas imaged lumbar vertebrae L1 to L5 should be moved to the left of figure 1.

20 Fig. 2 shows a frontal patient spine view, the spine having been partly derotated during preoperative planning, allowing performance of a step of the method of preoperative planning according to an embodiment of the invention.

The thoracic vertebrae 2 comprise thoracic vertebrae T1, T2, T3, T4,
25 T5, T6, T7, T8, T9, T10, T11, T12. The lumbar vertebrae 2 comprise lumbar vertebrae L1, L2, L3, L4, L5. The spine 1 is straight, what means all vertebrae 2 are vertically aligned. The represented spine 1 is a sane spine with respect to coronal plan. So, the spine 1, represented on figure 1, suffering from scoliosis, should be healed so as to become the straight spine
30 1 in coronal plan of figure 2, appearing to be sane with respect to coronal plan. Therefore, all imaged vertebrae 2 of figure 1 will have to be derotated,

i.e. to undergo a derotation, so as to become straight in coronal plan as on figure 2. This derotation will include indeed a rotation and a translation to be performed simultaneously.

5 Fig. 3 shows a frontal patient spine view, where a starting phase of translation and rotation, in a coronal plane, allowing performance of a step of the method of preoperative planning according to an embodiment of the invention. During derotation, intervertebral space is maintained.

10 One by one, each vertebra 2 will be simultaneously translated and rotated in the coronal plan of figure 3, so that the spine 1 becomes straight in coronal plan of figure 3. On figure 3, lumbar vertebrae L5 to L1 and thoracic vertebra T12 have already undergone such combined translation and rotation in coronal plan and are already vertically aligned in coronal plan. Thoracic vertebra T11 has just started its combined translation and rotation in coronal plan. Thoracic vertebrae T10 to T1 are still in their
15 original position corresponding to scoliosis of spine 1, waiting for derotation.

20 Fig. 4 shows a frontal patient spine view, where an ending phase of translation and rotation, in a coronal plane, allowing performance of a step of the method of preoperative planning according to an embodiment of the invention.

25 On figure 4, lumbar vertebrae L5 to L1 and thoracic vertebra T12 have already undergone such combined translation and rotation in coronal plan and are already vertically aligned in coronal plan. Thoracic vertebra T11 is about ending its combined translation and rotation in coronal plan. Thoracic vertebrae T10 to T1 are still in their original position corresponding to scoliosis of spine 1, waiting for derotation.

30 Fig. 5 shows a frontal patient spine view, where a starting phase of translation and rotation, in an axial plane, allowing performance of a step of the method of preoperative planning according to an embodiment of the invention.

One by one, each vertebra 2 will be simultaneously translated and rotated in the axial plan of figure 5, so that the spine 1 becomes straight in axial plan of figure 5. On figure 5, lumbar vertebrae L5 to L1 and thoracic vertebra T12 to T9 have already undergone such combined translation and rotation in axial plan and are already vertically aligned in axial plan. Thoracic vertebra T8 has just started its combined translation and rotation in axial plan. Thoracic vertebrae T7 to T1 are still in their original position corresponding to scoliosis of spine 1, waiting for derotation.

Fig. 6 shows a frontal patient spine view, where an ending phase of translation and rotation, in an axial plane, allowing performance of a step of the method of preoperative planning according to an embodiment of the invention.

On figure 6, lumbar vertebrae L5 to L1 and thoracic vertebra T12 to T9 have already undergone such combined translation and rotation in axial plan and are already vertically aligned in axial plan. Thoracic vertebra T8 is ending its combined translation and rotation in axial plan. Thoracic vertebrae T7 to T1 are still in their original position corresponding to scoliosis of spine 1, waiting for derotation.

Figures 3-6 have shown both derotations in coronal plan and in axial plan. In fact, both derotations may be performed the following way: combined translation in coronal plan and rotations respectively in coronal and axial plans are performed either successively or simultaneously with the imaged vertebrae 2 on display device during preoperative planning so that, at the end, spine 1 becomes aligned in coronal and axial plans, in a similar way as will be made with the real vertebrae later during operative treatment.

Fig. 7 shows a lateral patient spine view, with a high value of thoracic kyphosis, allowing performance of a step of the method of preoperative planning according to an embodiment of the invention. Spine curvature should be changed so as to provide for a closer to zero (or better a close to zero) value of sagittal vertical axis.

Spine 1 is articulated on sacral plate S1 of pelvis 3 and comprises vertebrae 2 among which thoracic vertebrae T1 to T12 and lumbar vertebrae L1 to L5. The lumbar lordosis is the curvature of curve C2 of spine 1 on a subset of lumbar vertebrae L1 to L5. It can be determined as the angle
5 between two directions D1 and D2 which correspond respectively to sacral plate S1 of pelvis orientation and to upper plate of lumbar vertebra L1 orientation. Its value on figure 7 is 71.4 degrees.

To change the value of lumbar lordosis, an intermediate marker 8 can be moved on the display device by the operator so as to change the
10 curvature of curve C2 between two end markers 7 and 9 which remain fixedly respectively located on first lumbar vertebra L1 and on sacral plate S1 of pelvis 3. By moving the intermediate marker 8, the curve C2 is also displaced, since intermediate marker 8 stays on this curve C2.

The intermediate marker 8 can be moved up and down along spine 1
15 axis in order to change curvature distribution as well as perpendicularly to spine 1 axis in order to change curvature direction and curvature amplitude. The bounds of this intermediate marker 8 displacement are along spine 1 axis the extreme lumbar vertebrae L1 and L5, and perpendicularly to spine 1 axis the maximum amplitude corresponding to maximal curvature that the
20 lumbar vertebrae L1 to L5 may bear without damage.

The thoracic kyphosis is the curvature of curve C1 of spine 1 on a subset of thoracic vertebrae T1 to T12. It can be determined as the angle between two directions D3 and D4 which correspond respectively to lower
25 plate of thoracic vertebra T12 orientation and to upper plate of thoracic vertebra T1 orientation. Its value on figure 7 is 50.7 degrees.

To change the value of thoracic kyphosis, an intermediate marker 5 can be moved on the display device by the operator so as to change the curvature of curve C1 between two end markers 4 and 6 which remain
30 fixedly respectively located on first thoracic vertebra T1 and on last thoracic vertebra T12 or preferably more precisely just in between last thoracic vertebra T12 and first lumbar vertebra L1. By moving the intermediate

marker 5, the curve C1 is also displaced, since intermediate marker 5 stays on this curve C1.

5 The intermediate marker 5 can be moved up and down along spine 1 axis in order to change curvature distribution as well as perpendicularly to spine 1 axis in order to change curvature direction and curvature amplitude. The bounds of this intermediate marker 5 displacement are along spine 1 axis the extreme thoracic vertebrae T1 and T12, and perpendicularly to spine 1 axis the maximum amplitude corresponding to maximal curvature that the thoracic vertebrae T1 to T12 may bear without damage.

10 The sagittal vertical axis value E1 is -115.4mm. This value should be brought close to zero, if possible and while respecting the scheduled values of lumbar lordosis and thoracic kyphosis for this specific patient, so that spine 1 becomes more balanced and may correspond to saner thoracic kyphosis and lumbar lordosis. On figure 7, the value of thoracic kyphosis, which is too high, should therefore be reduced.

15 Fig. 8 shows a lateral patient spine view, with a high value of lumbar lordosis, allowing performance of a step of the method of preoperative planning according to an embodiment of the invention. Spine curvature should be changed so as to provide for a closer to zero (or better a close to zero) value of sagittal vertical axis.

20 The value of lumbar lordosis is on figure 8 is 91.1 degrees. To change the value of lumbar lordosis, an intermediate marker 8 can be moved on the display device by the operator so as to change the curvature of curve C2 between two end markers 7 and 9 which remain fixedly respectively located on first lumbar vertebra L1 and on sacral plate S1 of pelvis 3. By moving the intermediate marker 8, the curve C2 is also displaced, since intermediate marker 8 stays on this curve C2.

25 The value of thoracic kyphosis is on figure 8 is 41.0 degrees. To change the value of thoracic kyphosis, an intermediate marker 5 can be moved on the display device by the operator so as to change the curvature of curve C1 between two end markers 4 and 6 which remain fixedly

respectively located on first thoracic vertebra T1 and on last thoracic vertebra T12 or preferably more precisely just in between last thoracic vertebra T12 and first lumbar vertebra L1. By moving the intermediate marker 5, the curve C1 is also displaced, since intermediate marker 5 stays
5 on this curve C1.

The sagittal vertical axis value E1 is 4.2mm. This value should be brought close to zero, if possible and while respecting the scheduled values of lumbar lordosis and thoracic kyphosis for this specific patient, so that spine 1 becomes more balanced and may correspond to saner thoracic
10 kyphosis and lumbar lordosis. On figure 8, the value of lumbar lordosis, which is too high, should therefore be reduced.

Fig. 9 shows a lateral patient spine view, with a close to zero value of sagittal vertical axis, allowing performance of a step of the method of preoperative planning according to an embodiment of the invention. Spine curvature is adapted because the value of sagittal vertical axis is already
15 close to zero.

The value of lumbar lordosis is on figure 9 is 86.0 degrees. To change the value of lumbar lordosis, an intermediate marker 8 can be moved on the display device by the operator so as to change the curvature of curve C2
20 between two end markers 7 and 9.

The value of thoracic kyphosis is on figure 9 is 34.5 degrees. To change the value of thoracic kyphosis, an intermediate marker 5 can be moved on the display device by the operator so as to change the curvature of curve C1 between two end markers 4 and 6.

The sagittal vertical axis value E1 is -1.5mm. This value is indeed very close to zero. On figure 9, corresponding spine 1 is well balanced and corresponds to sane thoracic kyphosis and lumbar lordosis.

Fig. 10 shows a lateral patient spine view, with a lumbar lordosis concentrated in the middle region of lumbar vertebrae, allowing
30 performance of a step of the method of preoperative planning according to an embodiment of the invention. Spine curvature should be changed so as to

provide for a closer to zero (or better a close to zero) value of sagittal vertical axis.

The value of lumbar lordosis is on figure 10 is 76.4 degrees. The lumbar lordosis is concentrated in the middle region of lumbar vertebrae 2; therefore intermediate marker 8 is halfway between end markers 7 and 9. To change the value of lumbar lordosis, intermediate marker 8 can be moved on the display device by the operator so as to change the curvature of curve C2 between two end markers 7 and 9.

The value of thoracic kyphosis is on figure 10 is 34.5 degrees. The thoracic kyphosis is concentrated in the middle region of thoracic vertebrae 2; therefore intermediate marker 5 is halfway between end markers 4 and 6. To change the value of thoracic kyphosis, intermediate marker 5 can be moved on the display device by the operator so as to change the curvature of curve C1 between two end markers 4 and 6.

The sagittal vertical axis value E1 is -53.1mm. This value should be brought close to zero, if possible and while respecting the scheduled values of lumbar lordosis and thoracic kyphosis for this specific patient, so that spine 1 becomes more balanced.

Fig. 11 shows a lateral patient spine view, with a lumbar lordosis concentrated in the lower region of lumbar vertebrae, allowing performance of a step of the method of preoperative planning according to an embodiment of the invention. Spine curvature should be changed so as to provide for a closer to zero (or better a close to zero) value of sagittal vertical axis.

The value of lumbar lordosis is on figure 11 is 68.0 degrees. The lumbar lordosis is concentrated in the lower region of lumbar vertebrae 2; therefore intermediate marker 8 is closer to end marker 9 than to end marker 7. The lumbar lordosis should not be so concentrated in the lower region of lumbar vertebrae 2 and should be better distributed. To change the value of lumbar lordosis, intermediate marker 8 can be moved on the display device

by the operator so as to change the curvature of curve C2 between two end markers 7 and 9.

The value of thoracic kyphosis is on figure 11 is 34.5 degrees. The thoracic kyphosis is concentrated in the middle region of thoracic vertebrae 2; therefore intermediate marker 5 is halfway between end markers 4 and 6.
5 To change the value of thoracic kyphosis, intermediate marker 5 can be moved on the display device by the operator so as to change the curvature of curve C1 between two end markers 4 and 6.

The sagittal vertical axis value E1 is -91.8mm. This value should be
10 brought close to zero, if possible and while respecting the scheduled values of lumbar lordosis and thoracic kyphosis for this specific patient, so that spine 1 becomes more balanced.

Fig. 12 shows a lateral patient spine view, with a lumbar lordosis concentrated in the upper region of lumbar vertebrae, allowing performance
15 of a step of the method of preoperative planning according to an embodiment of the invention. Spine curvature should be changed so as to provide for a closer to zero (or better a close to zero) value of sagittal vertical axis.

The value of lumbar lordosis is on figure 12 is 74.4 degrees. The
20 lumbar lordosis is concentrated in the upper region of lumbar vertebrae 2; therefore intermediate marker 8 is closer to end marker 7 than to end marker 9. The lumbar lordosis should not be so concentrated in the upper region of lumbar vertebrae 2 and should be better distributed. To change the value of lumbar lordosis, intermediate marker 8 can be moved on the display device
25 by the operator so as to change the curvature of curve C2 between two end markers 7 and 9.

The value of thoracic kyphosis is on figure 12 is 34.5 degrees. The thoracic kyphosis is concentrated in the middle region of thoracic vertebrae 2; therefore intermediate marker 5 is halfway between end markers 4 and 6.
30 To change the value of thoracic kyphosis, intermediate marker 5 can be

moved on the display device by the operator so as to change the curvature of curve C1 between two end markers 4 and 6.

5 The sagittal vertical axis value E1 is -61.7mm. This value should be brought close to zero, if possible and while respecting the scheduled values of lumbar lordosis and thoracic kyphosis for this specific patient, so that spine 1 becomes more balanced.

10 Fig. 13 shows a lateral patient spine view, with a thoracic kyphosis concentrated in the middle region of thoracic vertebrae, allowing performance of a step of the method of preoperative planning according to an embodiment of the invention. Spine curvature should be changed so as to provide for a closer to zero (or better a close to zero) value of sagittal vertical axis.

15 The value of lumbar lordosis is on figure 13 is 72.1 degrees. The lumbar lordosis is concentrated in the lower region of lumbar vertebrae 2; therefore intermediate marker 8 is closer to end marker 9 than to end marker 7. To change the value of lumbar lordosis, intermediate marker 8 can be moved on the display device by the operator so as to change the curvature of curve C2 between two end markers 7 and 9.

20 The value of thoracic kyphosis is on figure 13 is 34.5 degrees. The thoracic kyphosis is concentrated in the middle region of thoracic vertebrae 2; therefore intermediate marker 5 is halfway between end markers 4 and 6. To change the value of thoracic kyphosis, intermediate marker 5 can be moved on the display device by the operator so as to change the curvature of curve C1 between two end markers 4 and 6.

25 The sagittal vertical axis value E1 is -73.5mm. This value should be brought close to zero, if possible and while respecting the scheduled values of lumbar lordosis and thoracic kyphosis for this specific patient, so that spine 1 becomes more balanced.

30 Fig. 14 shows a lateral patient spine view, with a thoracic kyphosis concentrated in the lower region of thoracic vertebrae, allowing performance of a step of the method of preoperative planning according to

an embodiment of the invention. Spine curvature should be changed so as to provide for a closer to zero (or better a close to zero) value of sagittal vertical axis.

5 The value of lumbar lordosis is on figure 14 is 72.1 degrees. The lumbar lordosis is concentrated in the lower region of lumbar vertebrae 2; therefore intermediate marker 8 is closer to end marker 9 than to end marker 7. To change the value of lumbar lordosis, intermediate marker 8 can be moved on the display device by the operator so as to change the curvature of curve C2 between two end markers 7 and 9.

10 The value of thoracic kyphosis is on figure 14 is 26.5 degrees. The thoracic kyphosis is concentrated in the lower region of thoracic vertebrae 2; therefore intermediate marker 5 is closer to end marker 6 than to end marker 4. The thoracic kyphosis should not be so concentrated in the lower region of thoracic vertebrae 2 and should be better distributed. To change the value
15 of thoracic kyphosis, intermediate marker 5 can be moved on the display device by the operator so as to change the curvature of curve C1 between two end markers 4 and 6.

The sagittal vertical axis value E1 is -72.9mm. This value should be brought close to zero, if possible and while respecting the scheduled values
20 of lumbar lordosis and thoracic kyphosis for this specific patient, so that spine 1 becomes more balanced.

Fig. 15 shows a lateral patient spine view, with a thoracic kyphosis concentrated in the upper region of thoracic vertebrae, allowing performance of a step of the method of preoperative planning according to
25 an embodiment of the invention. Spine curvature should be changed so as to provide for a closer to zero (or better a close to zero) value of sagittal vertical axis.

The value of lumbar lordosis is on figure 15 is 72.1 degrees. The lumbar lordosis is concentrated in the lower region of lumbar vertebrae 2;
30 therefore intermediate marker 8 is closer to end marker 9 than to end marker 7. To change the value of lumbar lordosis, intermediate marker 8 can be

moved on the display device by the operator so as to change the curvature of curve C2 between two end markers 7 and 9.

5 The value of thoracic kyphosis is on figure 15 is 61.5 degrees. The thoracic kyphosis is concentrated in the upper region of thoracic vertebrae 2; therefore intermediate marker 5 is closer to end marker 4 than to end marker 6. The thoracic kyphosis should not be so concentrated in the upper region of thoracic vertebrae 2 and should be better distributed. To change the value of thoracic kyphosis, intermediate marker 5 can be moved on the display device by the operator so as to change the curvature of curve C1 between
10 two end markers 4 and 6.

The sagittal vertical axis value E1 is -68.7mm. This value should be brought close to zero, if possible and while respecting the scheduled values of lumbar lordosis and thoracic kyphosis for this specific patient, so that spine 1 becomes more balanced.

15 The invention has been described with reference to preferred embodiments. However, many variations are possible within the scope of the invention.

CLAIMS

1. Method of preoperative planning to correct spine (1) misalignment of a
5 patient, comprising a step of making a translation and a rotation, in a
sagittal plane, of each vertebra (2) of a set of several cervical and/or
thoracic (T1-T12) and/or lumbar (L1-L5) imaged spine vertebrae (2), so
that said set of imaged vertebrae (2) presents afterwards, in the sagittal
10 plane, the same cervical lordosis and/or the same thoracic kyphosis
and/or the same lumbar lordosis as a model adapted for said patient,
wherein it also comprises, before said step of making said translation
and said rotation in a sagittal plane a step of making a translation and
a rotation, in a coronal plane, of each vertebra (2) of said set of several
15 cervical and/or thoracic (T1-T12) and/or lumbar (L1-L5) imaged spine
vertebrae (2), so that said set of imaged vertebrae (2) becomes straight
in said coronal plane, and of making a rotation, in an axial plane, of
each vertebra (2) of said set of several cervical and/or thoracic (T1-
T12) and/or lumbar (L1-L5) imaged spine vertebrae (2), so that said
20 set of imaged vertebrae (2) becomes axially aligned.
2. Method of preoperative planning to correct spine (1) misalignment of a
patient according to claim 1, wherein it is applied to a set of several
thoracic (T1-T12) and several lumbar (L1-L5) imaged spine vertebrae
25 (2), so that said set of imaged vertebrae (2) presents, in the sagittal
plane, the same thoracic kyphosis and the same lumbar lordosis as a
model adapted for said patient.
3. Method of preoperative planning to correct spine (1) misalignment of a
30 patient according to claim 2, wherein it is applied to all thoracic (T1-
T12) and all lumbar (L1-L5) spine vertebrae (2), so that said patient

spine (1) presents, in the sagittal plane, the same thoracic kyphosis and the same lumbar lordosis as a model adapted for said patient.

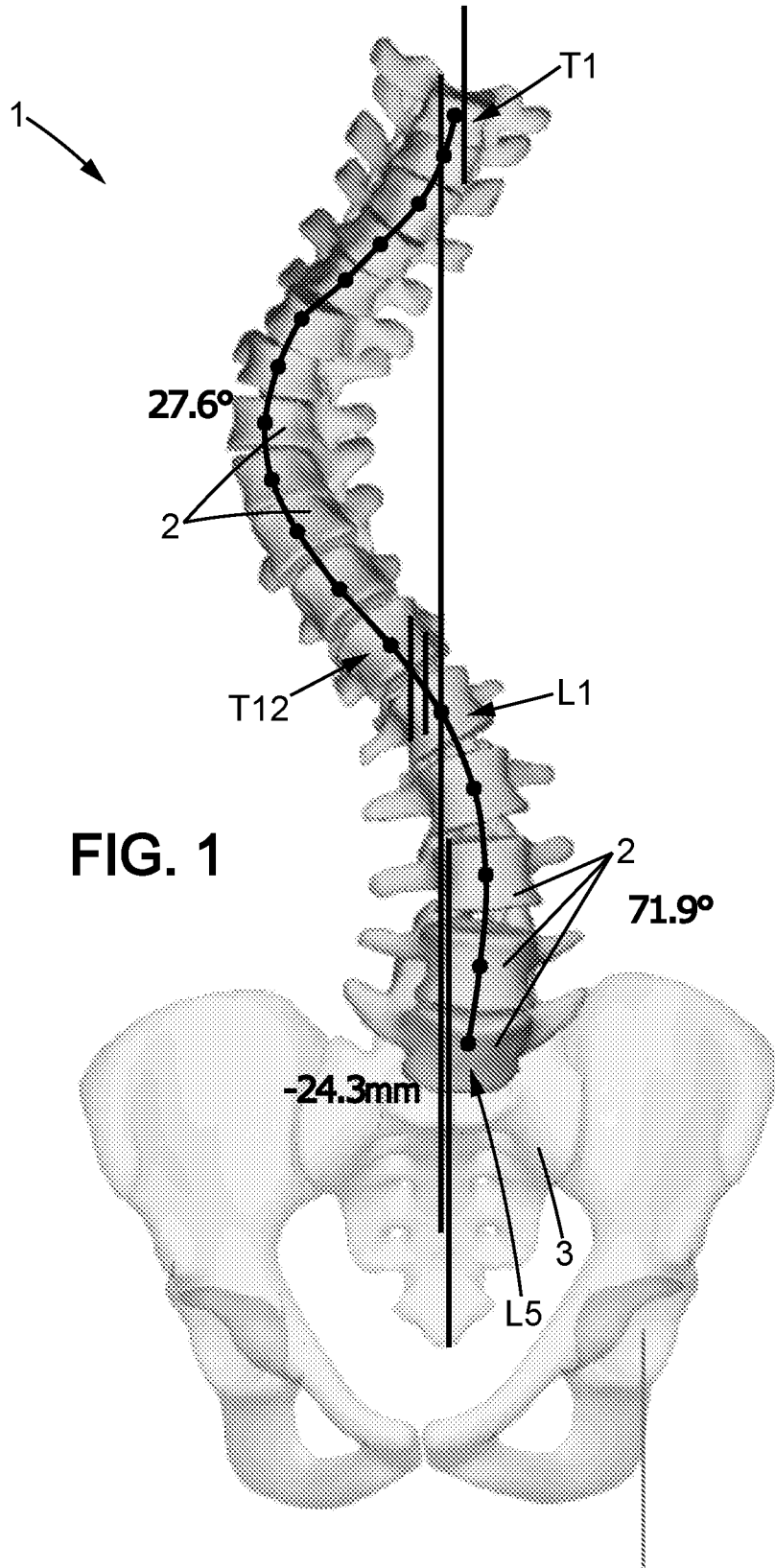
4. Method of preoperative planning to correct spine (1) misalignment of a patient according to any of claims 1 to 3, wherein:
- in said step of making a translation and a rotation in said coronal plane, said translation and rotation are performed simultaneously,
 - in said step of making a translation and a rotation in said sagittal plane, said translation and rotation are performed simultaneously.
5. Method of preoperative planning to correct spine (1) misalignment of a patient according to any of preceding claims, wherein it also comprises, after said steps of making translations and rotations, a step of pre-twisting at least one rod, to be integrated within said patient body to support said patient spine (1), according to position and orientation of said set of imaged vertebrae (2) after said step of making said translation and said rotation in a sagittal plane.
6. Method of preoperative planning to correct spine (1) misalignment of a patient according to claim 5, wherein in said step of pre-twisting, two rods are pre-twisted which are to be integrated respectively on both sides of said patient spine (1).
7. Method of preoperative planning to correct spine (1) misalignment of a patient according to any of claims 1 to 4, wherein it also comprises, after said steps of making translations and rotations, a step of editing a pattern of at least one pre-twisted rod to be integrated within said patient body to support said patient spine (1), according to position and orientation of said set of imaged vertebrae (2) after said step of making said translation and said rotation in a sagittal plane.

8. Method of preoperative planning to correct spine (1) misalignment of a patient according to any of preceding claims, wherein it also comprises, after said steps of making translations and rotations, a step of calculating the length of at least one rod, to be integrated within said patient body to support said patient spine (1), according to position and orientation of said set of imaged vertebrae (2) after said step of making said translation and said rotation in a sagittal plane.
9. Method of preoperative planning to correct spine (1) misalignment of a patient according to any of preceding claims, wherein said set of several thoracic (T1-T12) and/or lumbar (L1-L5) imaged spine vertebrae (2) is a 3D spine (1) image reconstructed from two 2D radiographic spine (1) images, preferably from a coronal image and a sagittal image.
10. Method of preoperative planning to correct spine (1) misalignment of a patient according to any of preceding claims,
wherein lumbar lordosis position is obtained by moving two end markers (7, 9) corresponding respectively to higher extreme lumbar vertebra (L1) and sacral plate (S1) and lumbar lordosis curvature (C2) is obtained by moving an intermediate marker (8) corresponding to an intermediate lumbar vertebra located between both extreme lumbar vertebrae (L1-L5),
and/or wherein thoracic kyphosis position is obtained by moving two end markers (4, 6) corresponding respectively to both extreme thoracic vertebrae (T1, T12) and thoracic kyphosis curvature (C1) is obtained by moving an intermediate marker (5) corresponding to an intermediate thoracic vertebra located between both extreme thoracic vertebrae (T1, T12),
and/or wherein cervical lordosis position is obtained by moving two end markers corresponding respectively to both extreme cervical vertebrae and cervical lordosis curvature is obtained by moving an intermediate

marker corresponding to an intermediate cervical vertebra located between both extreme cervical vertebrae.

- 5 11. Method of preoperative planning to correct spine (1) misalignment of a patient according to any of preceding claims, wherein said model is adapted for said patient first by getting an adapted lordosis from one or more patient based parameters and second by getting an adapted kyphosis from said adapted lordosis and from one or more patient based parameters.
- 10 12. Method of preoperative planning to correct spine (1) misalignment of a patient according to claim 11, wherein said adapted lordosis is obtained from patient pelvic incidence and from patient population type and preferably also from patient age.
- 15 13. Method of preoperative planning to correct spine (1) misalignment of a patient according to claim 12, wherein said adapted kyphosis is obtained from said adapted lordosis and from patient sagittal vertical axis (E1).
- 20 14. Method of preoperative planning to correct spine (1) misalignment of a patient according to claim 13, wherein said adapted kyphosis is obtained by varying said adapted lordosis curvature (C2) within a limited range, preferably plus or minus 10 degrees, while minimizing said patient sagittal vertical axis (E1).
- 25 15. Method of preoperative planning to correct spine (1) misalignment of a patient according to any of preceding claims, wherein said spine (1) misalignment comes from a scoliosis and/or from a degenerative spine.
- 30 16. A pre-twisted rod, to be integrated within a patient body to support a patient spine (1), which has been pre-twisted according to position and

orientation of a set of imaged vertebrae (2) after a step of making a translation and a rotation in a sagittal plane performed during a method of preoperative planning to correct spine (1) misalignment of a patient according to any of preceding claims.



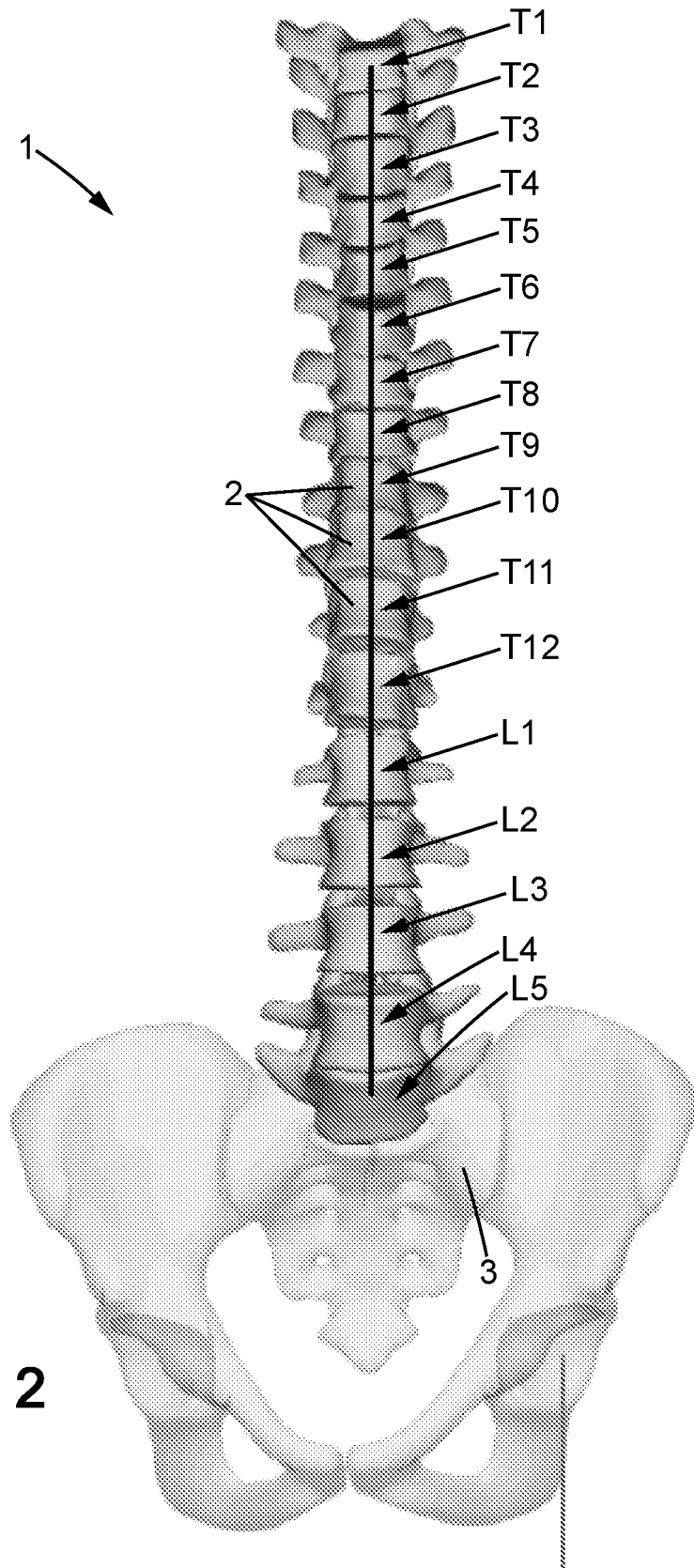


FIG. 2

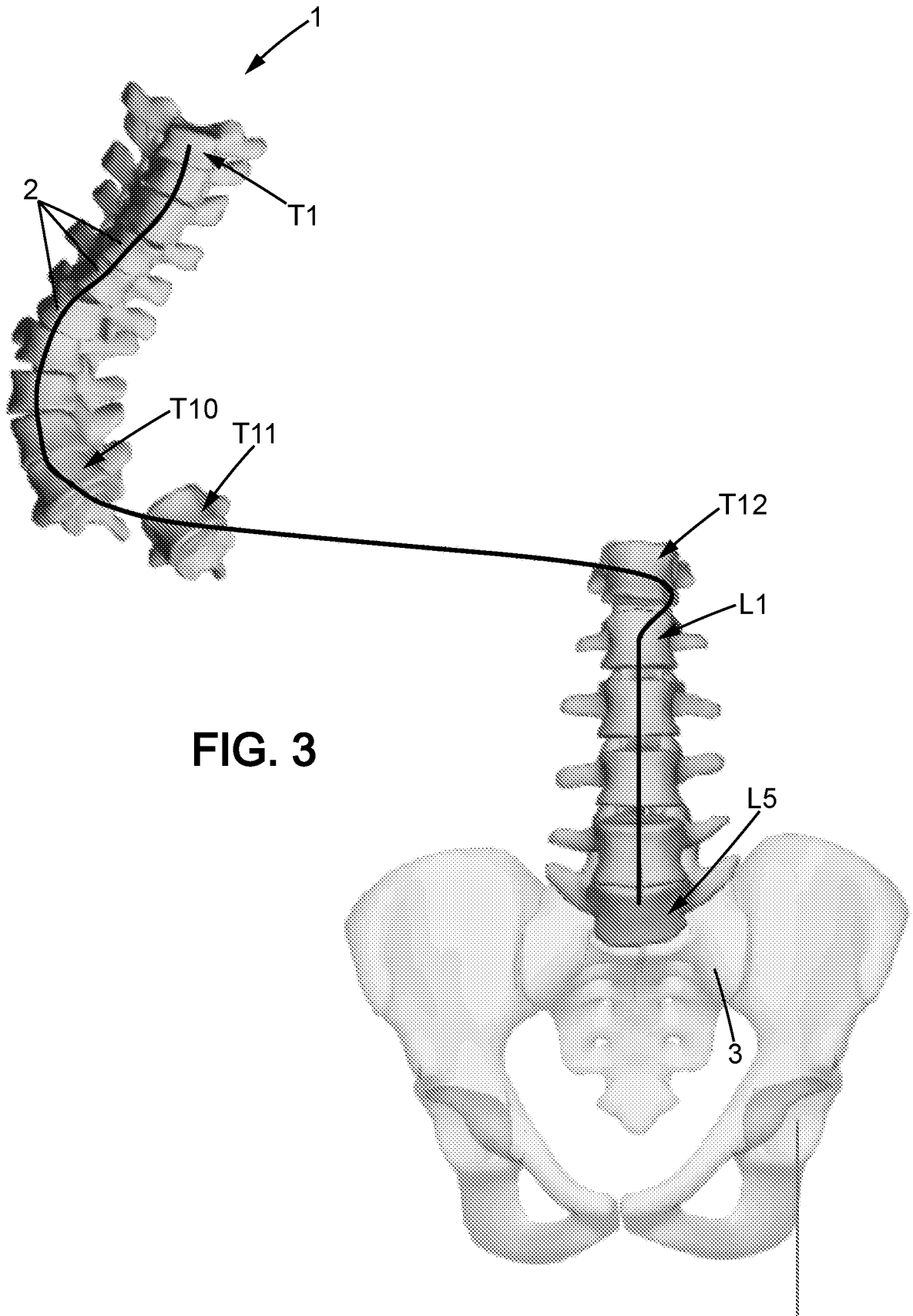


FIG. 3

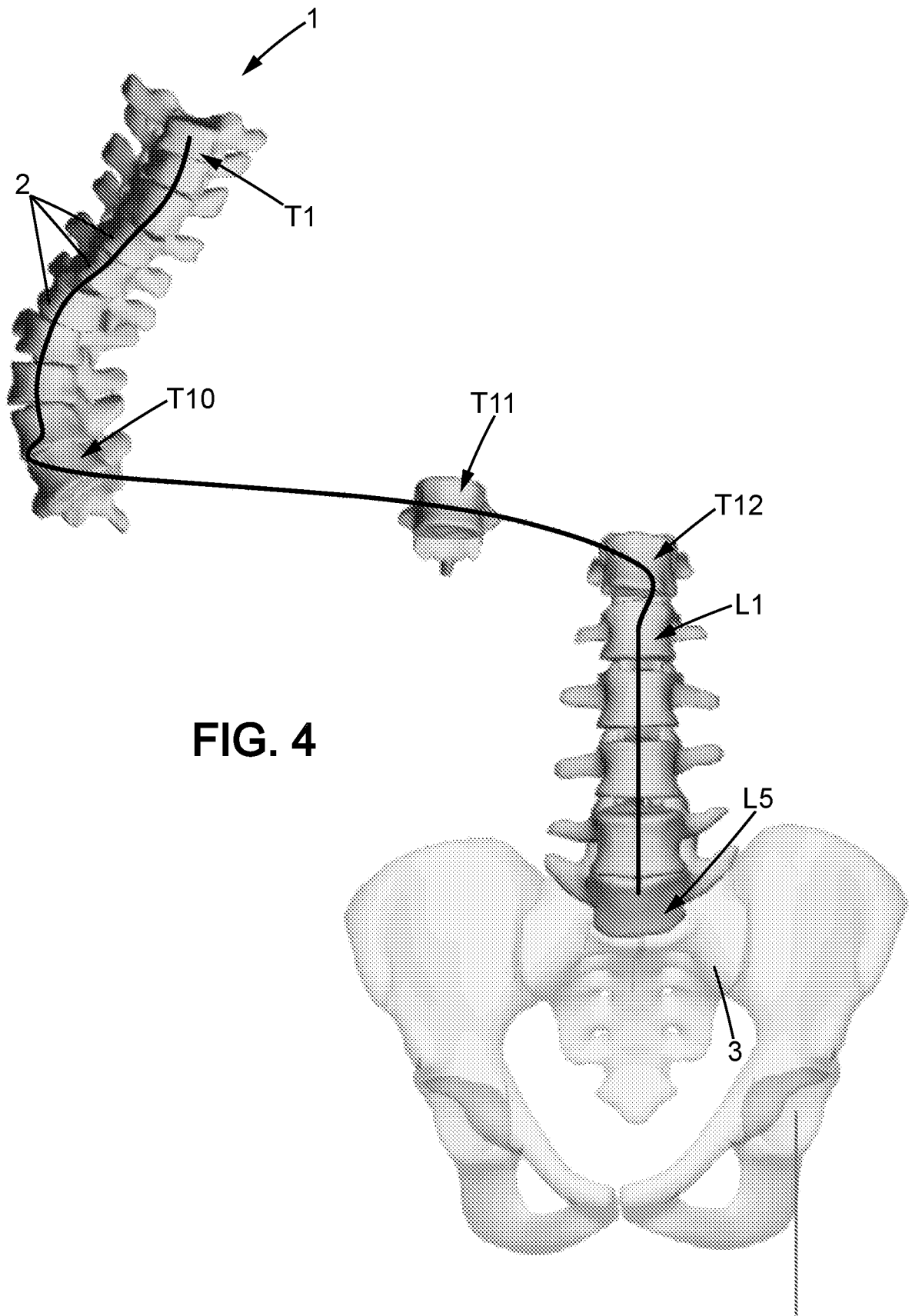


FIG. 4

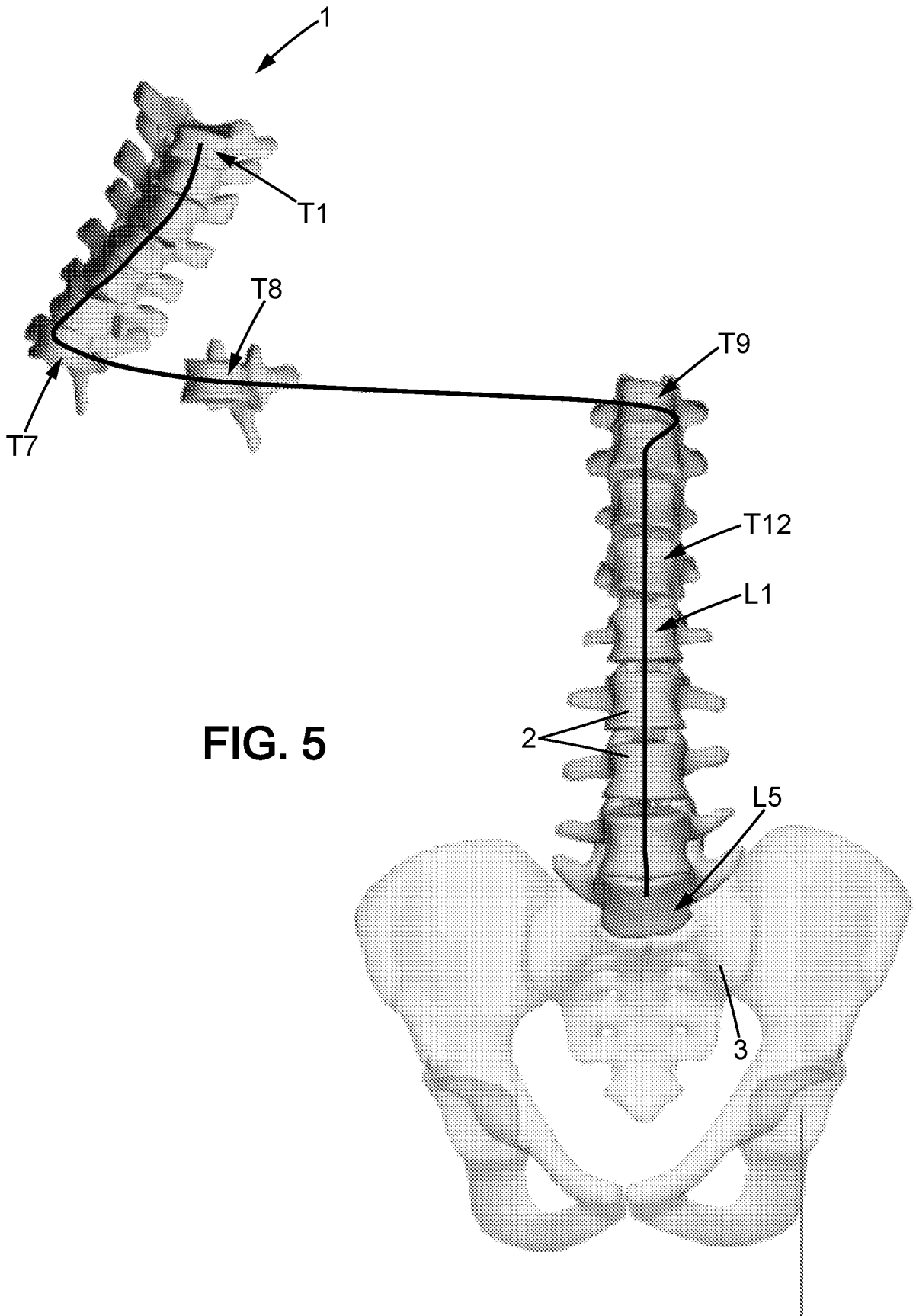


FIG. 5

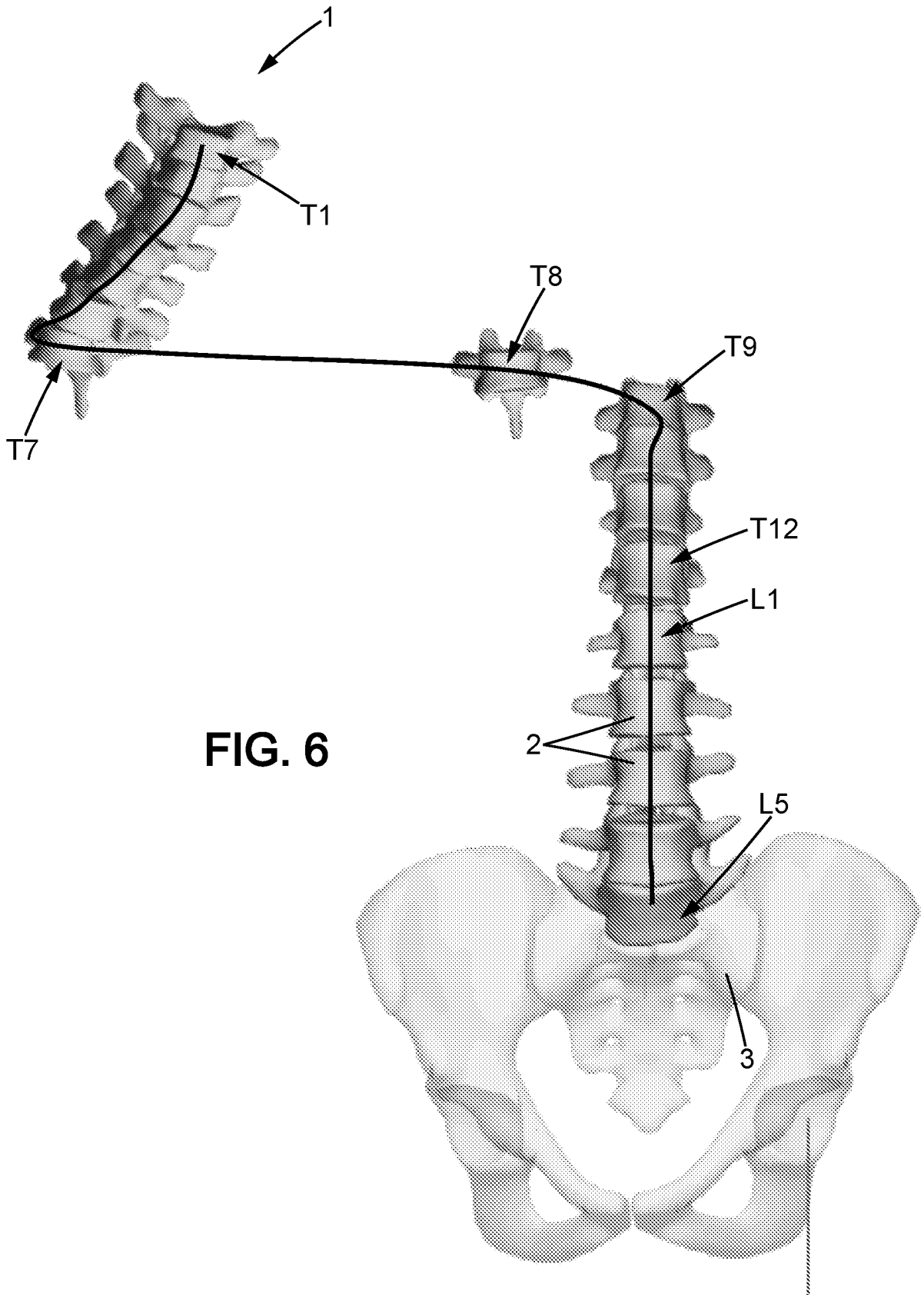
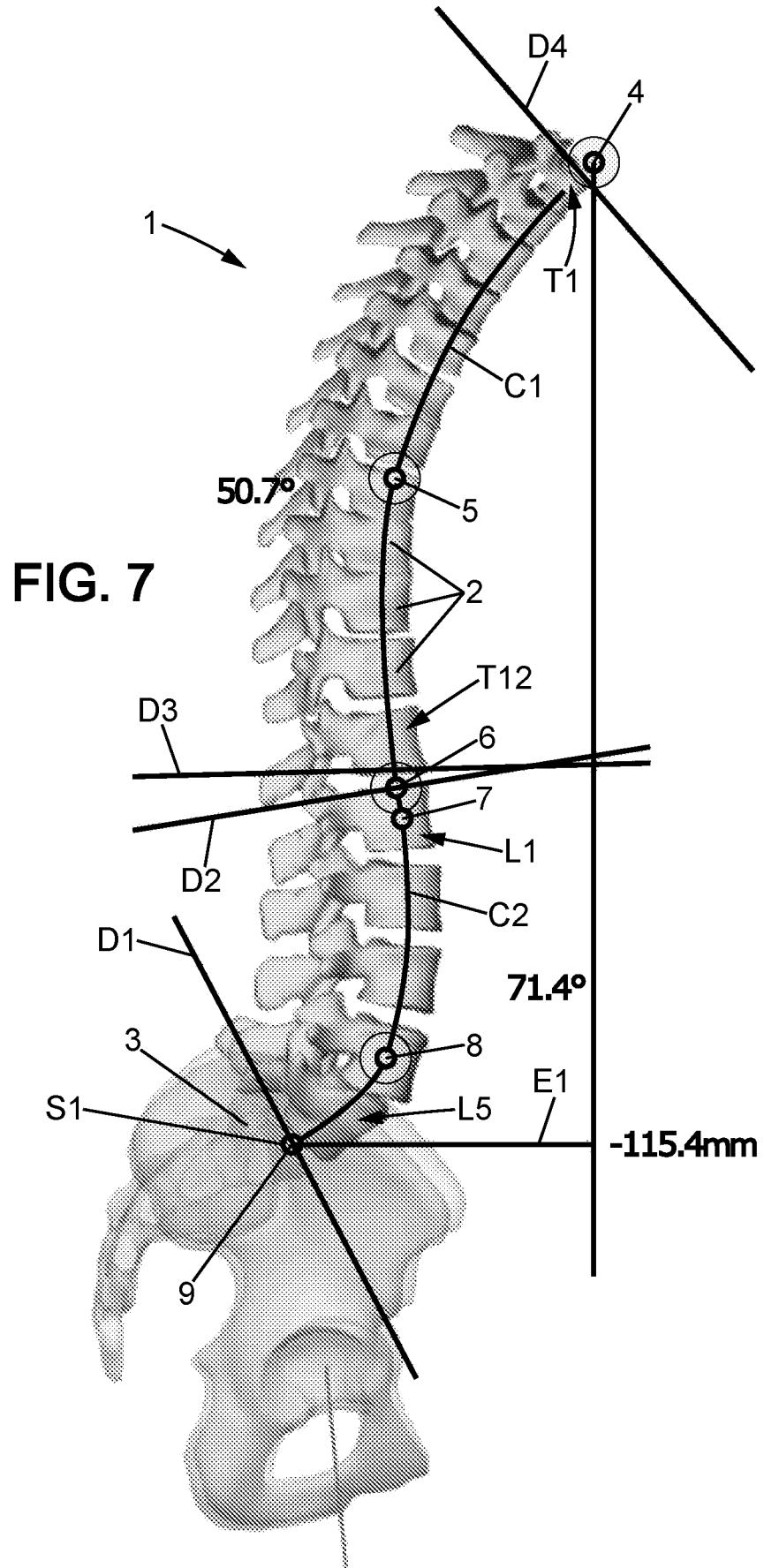
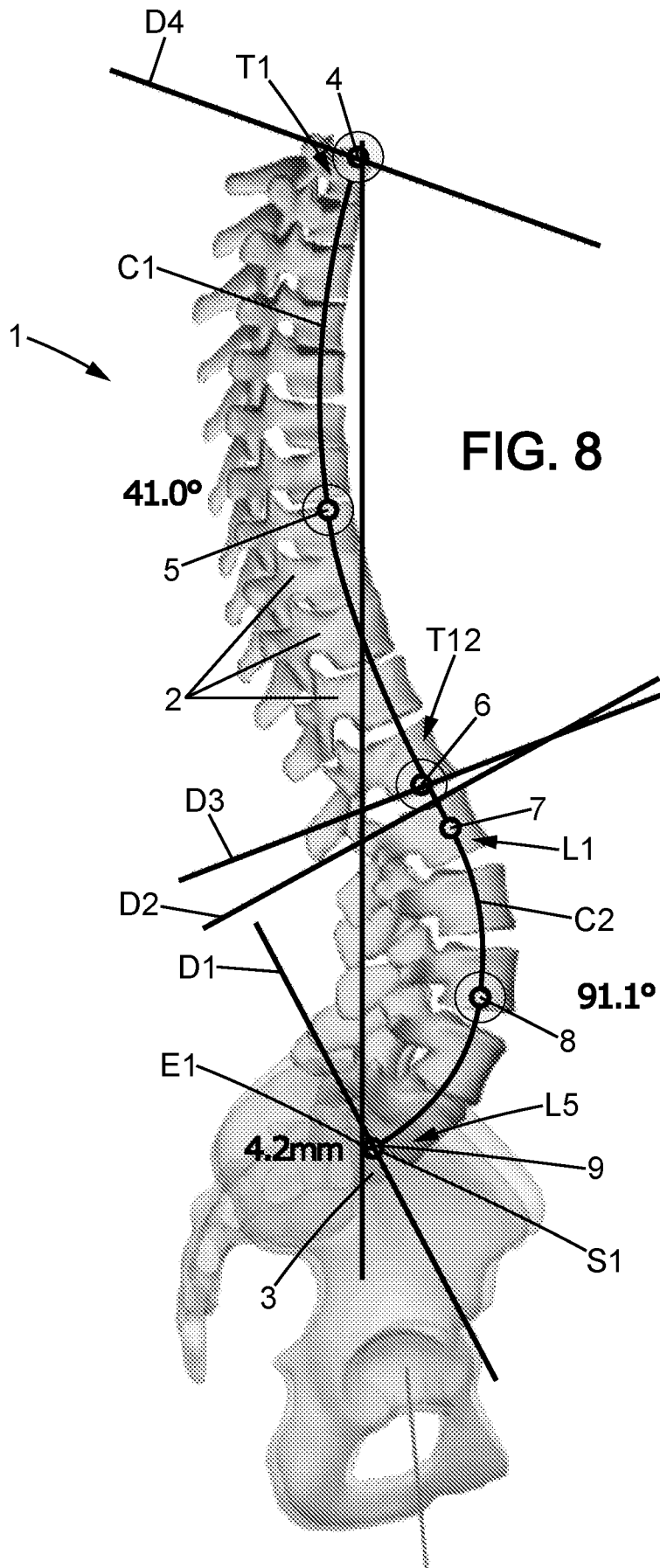
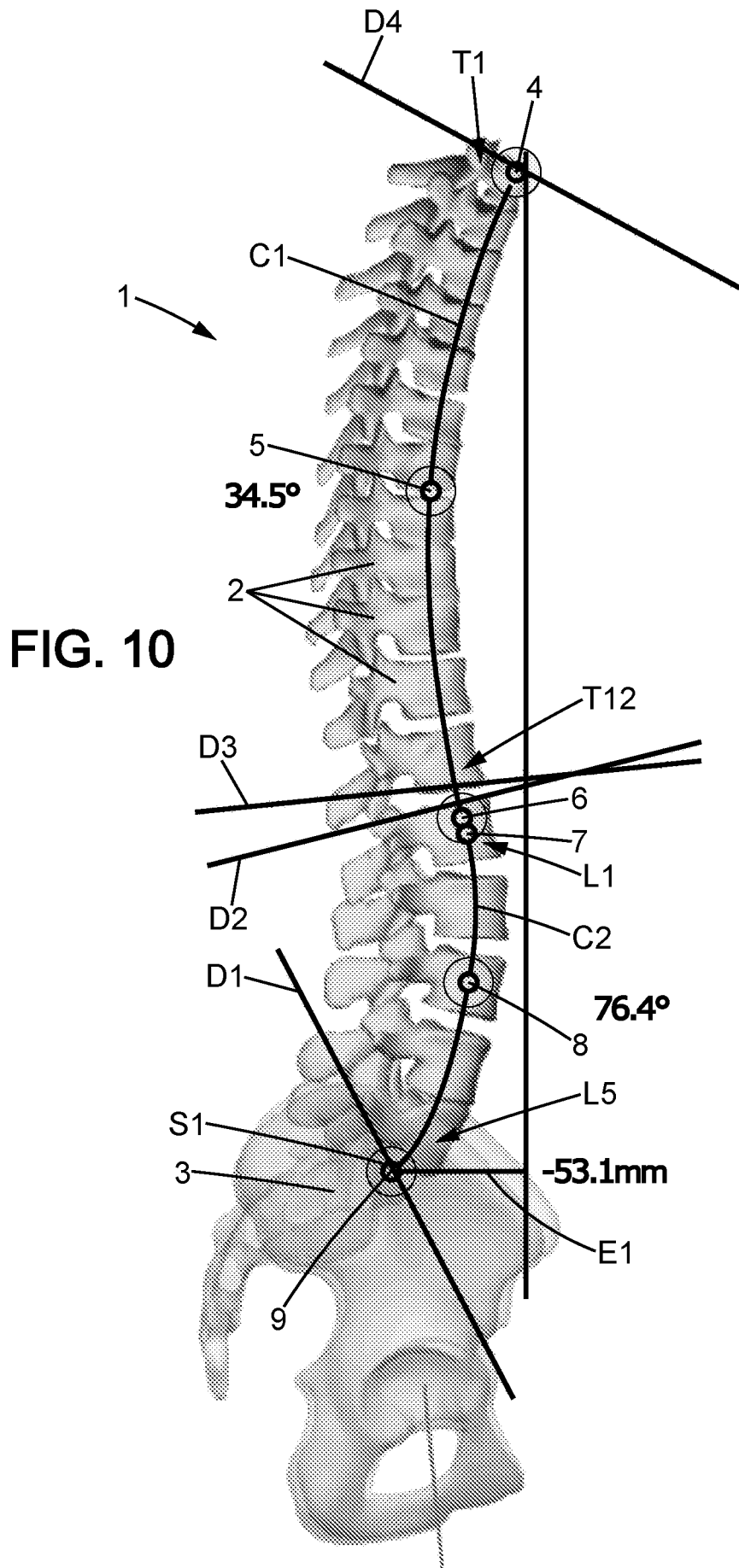
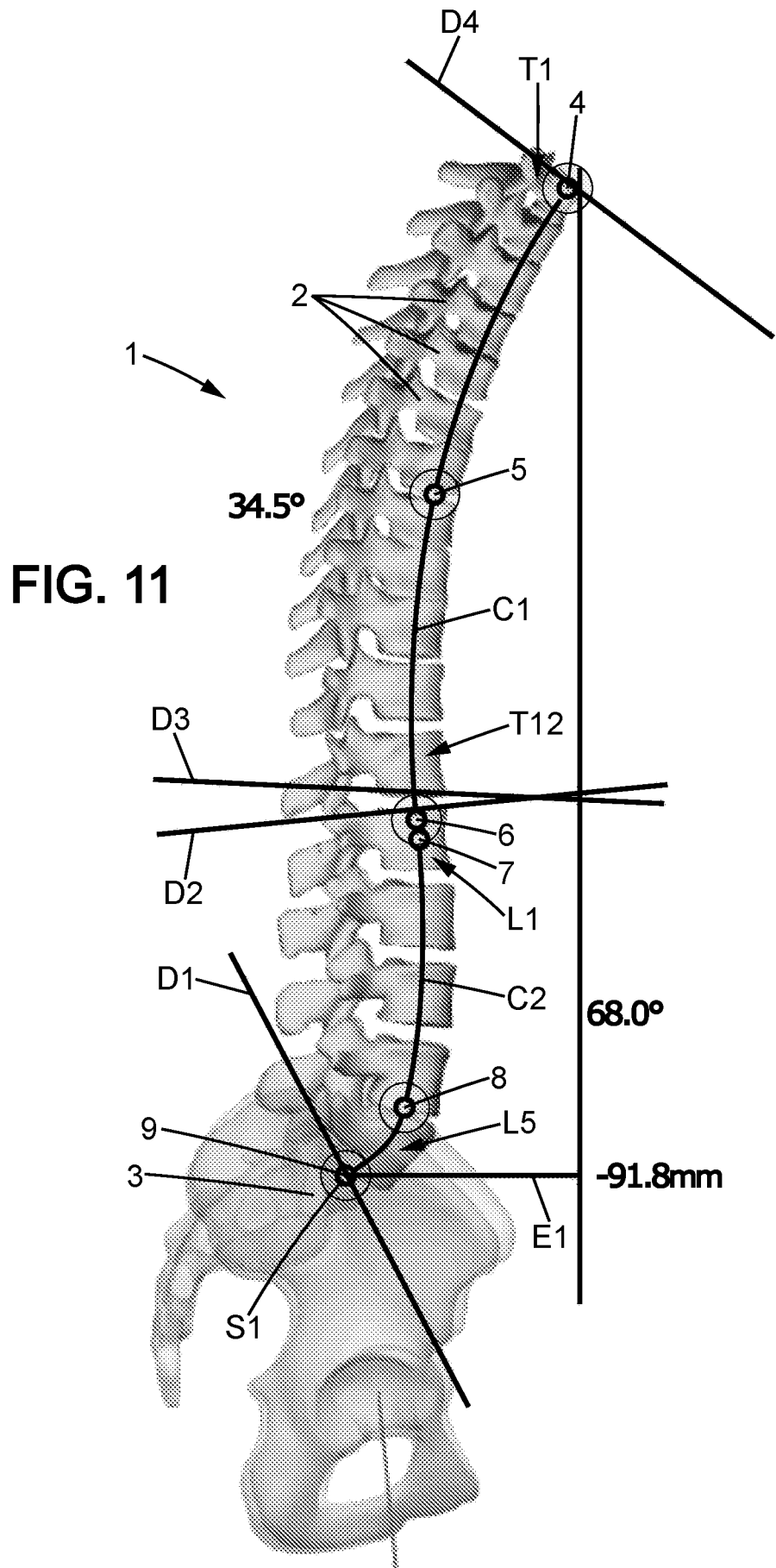


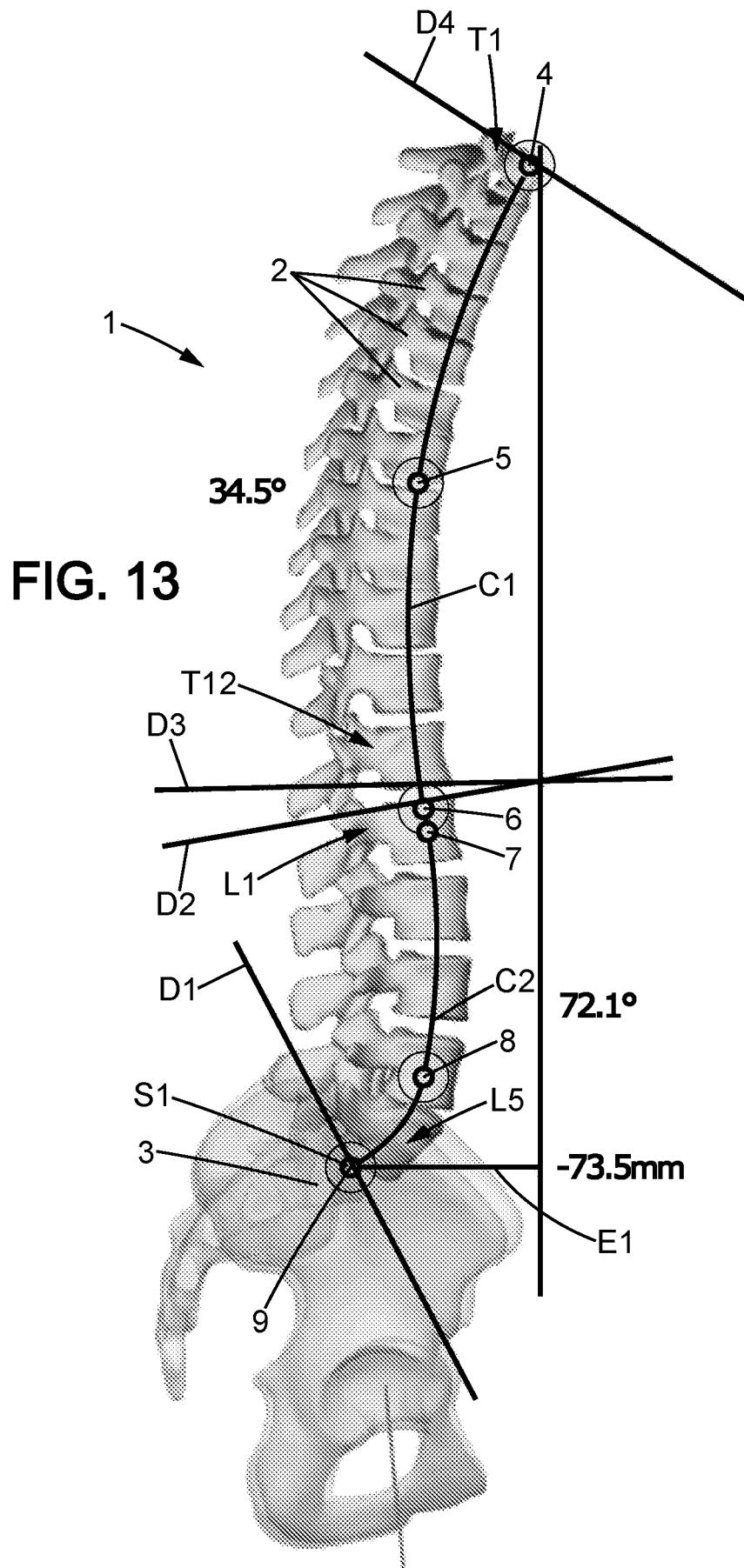
FIG. 6

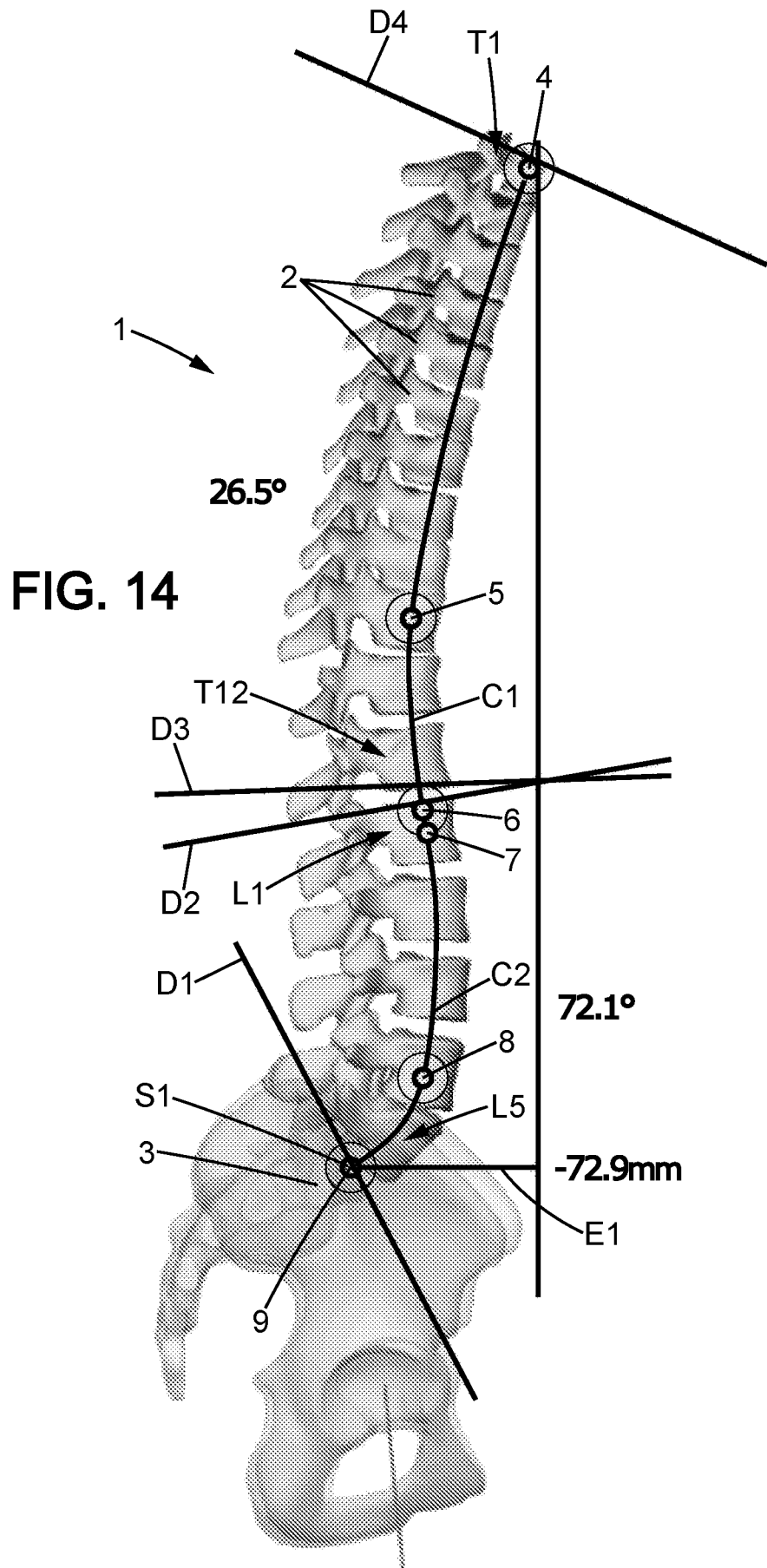












INTERNATIONAL SEARCH REPORT

International application No PCT/IB2015/002497
--

A. CLASSIFICATION OF SUBJECT MATTER
 INV. A61B34/10 A61B17/70
 ADD.

According to International Patent Classification (IPC) or to both national classification and IPC

B. FIELDS SEARCHED

Minimum documentation searched (classification system followed by classification symbols)
A61B

Documentation searched other than minimum documentation to the extent that such documents are included in the fields searched

Electronic data base consulted during the international search (name of data base and, where practicable, search terms used)

EPO-Internal, WPI Data

C. DOCUMENTS CONSIDERED TO BE RELEVANT

Category*	Citation of document, with indication, where appropriate, of the relevant passages	Relevant to claim No.
X	US 2015/100091 A1 (TOHMEH ANTOINE G [US] ET AL) 9 April 2015 (2015-04-09)	16
A	paragraphs [0002], [0126] - [0133], [0143] - [0147]; figures 33-37,50,51 -----	1-15
X	DE 10 2004 008870 A1 (ANDERS PETER [DE]) 14 October 2004 (2004-10-14)	16
A	paragraphs [0010], [0017], [0027]; figures 3c,3d -----	1
A	US 2005/119593 A1 (GALLARD EMERIC [FR] ET AL) 2 June 2005 (2005-06-02)	1-15
	paragraphs [0028] - [0045]; figures 1-8 -----	

Further documents are listed in the continuation of Box C.

See patent family annex.

* Special categories of cited documents :

"A" document defining the general state of the art which is not considered to be of particular relevance

"E" earlier application or patent but published on or after the international filing date

"L" document which may throw doubts on priority claim(s) or which is cited to establish the publication date of another citation or other special reason (as specified)

"O" document referring to an oral disclosure, use, exhibition or other means

"P" document published prior to the international filing date but later than the priority date claimed

"T" later document published after the international filing date or priority date and not in conflict with the application but cited to understand the principle or theory underlying the invention

"X" document of particular relevance; the claimed invention cannot be considered novel or cannot be considered to involve an inventive step when the document is taken alone

"Y" document of particular relevance; the claimed invention cannot be considered to involve an inventive step when the document is combined with one or more other such documents, such combination being obvious to a person skilled in the art

"&" document member of the same patent family

Date of the actual completion of the international search

28 July 2016

Date of mailing of the international search report

09/08/2016

Name and mailing address of the ISA/

European Patent Office, P.B. 5818 Patentlaan 2
 NL - 2280 HV Rijswijk
 Tel. (+31-70) 340-2040,
 Fax: (+31-70) 340-3016

Authorized officer

Maier, Christian

INTERNATIONAL SEARCH REPORT

Information on patent family members

International application No PCT/IB2015/002497

Patent document cited in search report		Publication date	Patent family member(s)	Publication date
US 2015100091	A1	09-04-2015	NONE	
DE 102004008870	A1	14-10-2004	NONE	
US 2005119593	A1	02-06-2005	AU 2003233358	A1 16-09-2003
			EP 1482846	A1 08-12-2004
			FR 2836818	A1 12-09-2003
			US 2005119593	A1 02-06-2005
			WO 03073946	A1 12-09-2003