

(19) World Intellectual Property
Organization
International Bureau



(43) International Publication Date
8 April 2004 (08.04.2004)

PCT

(10) International Publication Number
WO 2004/028580 A1

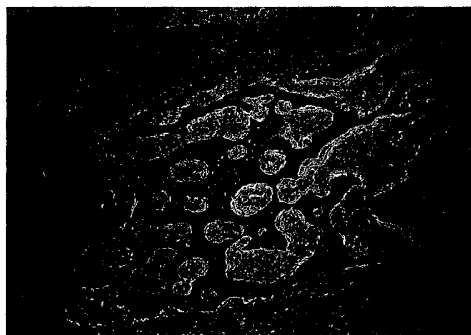
- (51) International Patent Classification⁷: A61L 27/44
- (21) International Application Number: PCT/KR2002/001839
- (22) International Filing Date: 30 September 2002 (30.09.2002)
- (25) Filing Language: Korean
- (26) Publication Language: English
- (71) Applicant (for all designated States except US): **REGEN BIOTECH, INC.** [KR/KR]; C9231 KIST, 39-1 Hawolgok-dong, Sungbuk-ku, 136-791 Seoul (KR).
- (72) Inventors; and
- (75) Inventors/Applicants (for US only): **KIM, In-San** [KR/KR]; #106-908 Dongsu Town, 1040 Maeho-dong, Soosung-ku, 706-140 Taegu (KR). **CHO, Byung Chae** [KR/KR]; #103-102 Dongsu-Myungmoon Town, 303 Bumou 4-dong, Soosung-ku, 706-822 Taegu (KR).
- (74) Agent: **LEE, Won-Hee**; 8th Fl., Sung-ji Heights II, 642-16 Yoksam-dong, Kangnam-ku, 135-080 Seoul (KR).
- (81) Designated States (national): AE, AG, AL, AM, AT, AU, AZ, BA, BB, BG, BR, BY, BZ, CA, CH, CN, CO, CR, CU, CZ, DE, DK, DM, DZ, EC, EE, ES, FI, GB, GD, GE, GH, GM, HR, HU, ID, IL, IN, IS, JP, KE, KG, KP, KZ, LC, LK, LR, LS, LT, LU, LV, MA, MD, MG, MK, MN, MW, MX, MZ, NO, NZ, OM, PH, PL, PT, RO, RU, SD, SE, SG, SI, SK, SL, TJ, TM, TN, TR, TT, TZ, UA, UG, US, UZ, VC, VN, YU, ZA, ZM, ZW.
- (84) Designated States (regional): ARIPO patent (GH, GM, KE, LS, MW, MZ, SD, SL, SZ, TZ, UG, ZM, ZW), Eurasian patent (AM, AZ, BY, KG, KZ, MD, RU, TJ, TM), European patent (AT, BE, BG, CH, CY, CZ, DE, DK, EE, ES, FI, FR, GB, GR, IE, IT, LU, MC, NL, PT, SE, SK, TR), OAPI patent (BF, BJ, CF, CG, CI, CM, GA, GN, GQ, GW, ML, MR, NE, SN, TD, TG).
- Published:
— with international search report

[Continued on next page]

(54) Title: BONE-FILLING COMPOSITION FOR STIMULATING BONE-FORMING AND BONE-CONSOLIDATION COMPRISING CALCIUM SULFATE AND VISCOUS BIOPOLYMERS



b



(57) Abstract: The present invention relates to a composition for bone-filling, more particularly, to a bone-filling composition for stimulating bone-formation and bone consolidation comprising calcium sulfate and viscous biopolymers. The composition of the present invention can easily be administered into the missing part of injured bone. Since the composition of the present invention does not diffuse to surrounding organs, it can effectively be used for bone-filling material suitable for body.

WO 2004/028580 A1



For two-letter codes and other abbreviations, refer to the "Guidance Notes on Codes and Abbreviations" appearing at the beginning of each regular issue of the PCT Gazette.

BONE-FILLING COMPOSITION FOR STIMULATING
BONE-FORMING AND BONE-CONSOLIDATION
COMPRISING CALCIUM SULFATE AND VISCOUS
BIOPOLYMERS

5

FIELD OF THE INVENTION

The present invention relates to a composition for bone-filling, more particularly, to a bone-filling composition for stimulating bone-formation and bone-consolidation comprising calcium sulfate and viscous biopolymers, and a use thereof for stimulating bone-formation and bone-consolidation.

BACKGROUND ART OF THE INVENTION

15 Recently, bone-loss is often caused by a disease or a car accident, so that supplementing bone-loss is importantly required. Bone-transplantation is one way to supplement bone-loss and more preferably bone-filling composition is used. Bone-extension technique
20 is performed today to extend one's height in stature or to correct undersized jaws, for which bone-filling composition is also required a lot.

Bone-extension technique is to stimulate bone-

growth, especially growth in height, by stretching based on the theory that "Tension forces stimulate histogenesis". Bone-extension technique was first devised for the growth of limb bones but has been widely used for jawbone extension. Jawbone extension method is one of techniques performed in the field of cranial jaw facial surgery, which can improve facial ratio not by cutting bone but by moving facial bones gradually by fixing bone-stretching apparatus to retreated parts of jawbone and central facial form.

Bone-extension technique has been successfully used for supplementing the loss of long bone since Ilizarov found out biomechanical elements for bone-extension (Ilizarov GA, *J. Dis. Orthop. Inst.*, 48(1): 1, 1988; Ilizarov GA, *Clin. Ortho.*, 239: 263, 1989; Ilizarov GA, *Clin. Ortho.*, 238: 249, 1989). It is important for performing the successful bone-extension to keep blood circulation in the part of bone-extension and to fix external fixator stably to both sides of joint part of cortical bone, resulting in the stimulation of bone-consolidation by gradual extension of bone (White SH, *J. Bone Joint Surgery*, 72-B: 350, 1990; White SH, *Orthop. Clin. North. Amer.*, 22: 569, 1991; Fishgrund J., Paley D., Sulter D., *Clin. Orthop.*, 301: 31, 1994).

The period of bone-consolidation depends on extension part of bones such as facial bone or long bone, blood circulation condition, the age of a patient, etc. Bone-consolidation of craniofacial bone takes 3-5 weeks for children and 6-12 weeks for adults after bone-extension, while it takes 3-6 months in long bone regardless of age. Performing bone-extension for craniofacial bone has a couple of problems; one is carrying high possibility of complications and the other is postponing the return to normal life due to the long bone-consolidation time. Precisely, the treatment after bone-extension takes 2-4 months composing of latent phase, bone-extension phase and bon-consolidation phase.

According to Charls and Sailer's report, extending 1 mm a day shows stronger biochemical and physiological characteristics than extending 2-3 mm a day (Carls & Sailer, *J. Craniomaxillofac Surg.*, 94: 152, 1994). Ilizarov has also reported that extending 1 a day showed best results while extending 0.5 mm a day caused premature bone-consolidation and extending 2 mm a day caused undesirable changes in extended tissues (Ilizarov, *J. Dis. Orthop. Inst.*, 48(1): 1, 1988; Ilizarov, *Clin. Ortho* 239: 263, 1989). In addition, it has also been known that consecutive extending causes

the least damage in tissues but the best development of capillary vessels and bone-formation. Therefore, shortening the period of bone-extension and bone-consolidation can contribute to prevent possible complications and to make a patient return to normal life early. In order to shorten the period of bone-extension and bone-consolidation, bone-filling composition is used to stimulate bone-formation and bone-consolidation.

10 Meanwhile, autobone-graft, treated homograft, heterograft and bone graft substitute have been known to stimulate bone-formation. Autobone-graft is used for the treatment of joint-agglutination or non-agglutinational fracture, or for avoiding damage and void caused by infection, tumor and operation by supplementing bone cavity or bone loss. Transplanted autobone is adsorbed well, resulting in re-circulation of blood. At this time, osteoprogenitor cells are differentiated to bony osteogenesis cells and the activation thereof stimulates bone-regeneration as well as treats bone-loss. However, autobone-graft has problems such as limitation in the amount of extraction and high morbidity caused by the secondary operation for the part of donation. Thus, bone morphogenic protein or other bone-grafting substitute is used to

induce bone-regeneration at extended sites. Bone morphogenic protein is regarded as the strongest bone-inducing material but is limited in clinical use because it is very expensive and hard to obtain.

5

Calcium sulfate is a kind of bone-filling material that is suitable for human body and induces the growth of bony osteogenesis cells and blood vessels as well as stimulates bone-consolidation in the early stage. This material is contribute to construct a normal bone structure by stimulating new bone-formation in a proper condition, plays as a defense shield during bone-healing by preventing the growth of unnecessary connecting tissues and can be substituted with bone during the recovery process. Beeson confirmed by the experiment with dogs that calcium sulfate injected into frontal sinus of dogs induced bone-regeneration within 4-6 weeks (Beeson W., *Arch Otolaryngol*, 107: 664, 1981), and Pecora et al. also reported bone-healing effect of calcium sulfate injected into bone-loss area of mouse jawbone that was observed partly or over the whole area three weeks after injection (Pecora G., Andreana S., Margarone III JE., Covani U., Sottosanti JS., *Oral Surg. Oral Med. Oral Pathol. Oral Radio Endod.*, 84: 434, 1997). According to Pelter's report, calcium sulfate

25

was safe to be administered to various types of bone-loss patients, stimulated bone-regeneration as being absorbed in a body within several weeks or several months and did not cause any complication or any danger (Pelter LF., *Am. J. Surg.*, 97(3): 311, 1959). However, the conventional calcium sulfate used as a bone-filling composition for bone-regeneration is difficult to be injected in bone-loss area because the composition is in a form of tablets or powder. In order to inject that composition, operation with a scar is unavoidable, which suffers patients.

Thus, the present inventors have tried to improve the way to administer calcium sulfate. As a result, the present inventors prepared a gel type composition containing calcium sulfate and viscous polymer, and accomplished the present invention by confirming that the composition of the invention can easily be administered into the bone-loss area by injection, does not diffuse to surrounding organs and shortens the bone-consolidation period by stimulating bone-formation and bone-consolidation.

SUMMARY OF THE INVENTION

It is an object of the present invention to provide a gel type bone-filling composition stimulating bone-formation and bone-consolidation that is easily administered into the missing part of injured bone and stays longer in that area.

BRIEF DESCRIPTION OF THE DRAWINGS

FIG. 1 is a photograph showing the pills of calcium sulfate that are used in the preparation of the composition of the present invention,

FIG. 2 is a photograph showing the setting of an external fixator to a test animal as performing bone extension operation using the composition of the present invention,

FIG. 3A is a photograph showing the extent of bone-consolidation in a control group 1 that was measured with radio-assay 3 weeks after bone extension, particularly the control group 1 was injected with only carboxymethylcellulose and was induced to have 1 mm extension per day for 10 days,

FIG. 3B is a photograph showing the extent of bone-consolidation in a control group 1 that was measured with radio-assay 6 weeks after bone extension, particularly the control group 1 was injected with only
5 carboxymethylcellulose and was induced to have 1 mm extension per day for 10 days,

FIG. 3C is a photograph showing the extent of bone-consolidation in a control group 2 that was
10 measured with radio-assay 3 weeks after bone extension, particularly the control group 1 was injected with only carboxymethylcellulose and was induced to have 2 mm extension per day for 5 days,

15 FIG. 3D is a photograph showing the extent of bone-consolidation in a control group 2 that was measured with radio-assay 6 weeks after bone extension, particularly the control group 2 was injected with only carboxymethylcellulose and was induced to have 2 mm
20 extension per day for 5 days,

FIG. 4A is a photograph showing the extent of bone-consolidation in a calcium sulfate group 1 that was measured with radio-assay 3 weeks after bone
25 extension, particularly the calcium sulfate group 1 was

injected with the composition of the present invention and was induced to have 1 mm extension per day for 10 days,

5 FIG. 4B is a photograph showing the extent of bone-consolidation in a calcium sulfate group 1 that was measured with radio-assay 6 weeks after bone extension, particularly the calcium sulfate group 1 was injected with the composition of the present invention
10 and was induced to have 1 mm extension per day for 10 days,

 FIG. 5A is a photograph showing the extent of bone-consolidation in a calcium sulfate group 2 that
15 was measured with radio-assay 3 weeks after bone extension, particularly the calcium sulfate group 2 was injected with the composition of the present invention and was induced to have 2 mm extension per day for 5 days,

20 FIG. 5B is a photograph showing the extent of bone-consolidation in a calcium sulfate group 2 that was measured with radio-assay 6 weeks after bone extension, particularly the calcium sulfate group 2 was
25 injected with the composition of the present invention

and was induced to have 2 mm extension per day for 5 days,

FIG. 6A is a photograph showing the histological section of a control group 1 3 weeks after bone extension, particularly the group was injected with only carboxymethylcellulose and was induced to have 1 mm extension per day for 10 days,

Arrows: the first cutting parts

10

FIG. 6B is a photograph showing the histological section of a control group 1 6 weeks after bone extension, particularly the group was injected with only carboxymethylcellulose and was induced to have 1 mm extension per day for 10 days,

Arrows: the first cutting parts

FIG. 6C is a photograph showing the new bone-formation at the edge of bone extension region in a control group 1 injected carboxymethylcellulose only and induced to have 1 mm extension per day for 10 days, which was confirmed by hematoxylin & eosin staining,

A: osteoblasts, B: fibrous tissues

FIG. 7A is a photograph showing the histological

25

section of a control group 2 3 weeks after bone extension, particularly the group was injected with only carboxymethylcellulose and was induced to have 2 mm extension per day for 5 days,

5 Arrows: the first cutting parts

FIG. 7B is a photograph showing the histological section of a control group 2 6 weeks after bone extension, particularly the group was injected with
10 only carboxymethylcellulose and was induced to have 2 mm extension per day for 5 days,

Arrows: the first cutting parts

FIG. 7C is a photograph showing the new bone-
15 formation at the edge of bone extension region in a control group 2 injected carboxymethylcellulose only and induced to have 2 mm extension per day for 5 days, which was confirmed by hematoxylin & eosin staining,

A: osteoblasts, B: fibrous tissues

20

FIG. 8A is a photograph showing the histological section of a calcium sulfate group 1 3 weeks after bone extension, particularly the group was injected with the composition of the present invention and was induced to
25 have 1 mm extension per day for 10 days,

Arrows: the first cutting parts

FIG. 8B is a photograph showing that the center
of the extended region was filled with osteoblasts and
5 fibrous tissues, which was confirmed by hematoxylin &
eosin staining with the histological section of FIG. 8A,

A: osteoblasts

B: fibrous tissues

FIG. 8C is a photograph showing the histological
10 section of a calcium sulfate group 1 6 weeks after bone
extension, particularly the group was injected with the
composition of the present invention and was induced to
have 1 mm extension per day for 10 days,

Arrows: the first cutting parts

15

FIG. 8D is a photograph showing the new bone-
formation over the whole extended region, which was
confirmed by hematoxylin & eosin staining with the
histological section of FIG. 8C,

20

FIG. 9A is a photograph showing the histological
section of a calcium sulfate group 2 3 weeks after bone
extension, particularly the group was injected with the
composition of the present invention and was induced to
25 have 2 mm extension per day for 5 days,

Arrows: the first cutting parts

FIG. 9B is a photograph showing that bone-formation was begun from the edge and fibrous interzone was connected with the extended area, which was confirmed by hematoxylin & eosin staining with the histological section of FIG. 9A,

FIG. 9C is a photograph showing the histological section of a calcium sulfate group 2 6 weeks after bone extension, particularly the group was injected with the composition of the present invention and was induced to have 2 mm extension per day for 5 days,

Arrows: the first cutting parts

15

FIG. 9D is a photograph showing the new bone-formation in half of extended area, which was confirmed by hematoxylin & eosin staining with the histological section of FIG. 9C.

20

A: osteoblasts

B: fibrous tissues

DETAILED DESCRIPTION OF THE INVENTION

To achieve the above object, the present invention provides a gel type composition for bone-

filling comprising calcium sulfate and viscous biopolymer.

The present invention also provides a use thereof for stimulating bone-formation and bone-consolidation.

5

Further features of the present invention will appear hereinafter.

The present invention provides a gel type composition for bone-filling comprising calcium sulfate and viscous biopolymer.

10

The composition of the present invention consists of

a) mixture (20~80 weight%) consisting of CaSO_4 (90~99 weight%) and CaCO_3 , MgCO_3 and $\text{CaCO}_3 \cdot \text{MgCO}_3$ (1~10 weight%); and

15

b) viscous biopolymer (80~20%)

CaSO_4 is the chief ingredient of the composition of the present invention and one or more inorganic salts selected from a group consisting of CaCO_3 , MgCO_3 , $\text{CaCO}_3 \cdot \text{MgCO}_3$ and the mixture of them can be added to the composition. In the preferred embodiments of the present invention, it is preferable that CaSO_4 takes 90~99 weight% of the total weight of inorganic salts and CaCO_3 , MgCO_3 , $\text{CaCO}_3 \cdot \text{MgCO}_3$ take 1~10 weight%. It is

25

more preferable that CaSO_4 takes 98~99 weight%, CaCO_3 does 0.3~1 weight%, MgCO_3 does 0.3~1 weight% and $\text{CaCO}_3 \cdot \text{MgCO}_3$ does 0.5~1 weight% for the total weight of the composition. Calcium sulfate is a less expensive bone-
5 filling material and generally provided as a highly purified powder or pills (see FIG. 1). When calcium sulfate is absorbed in bone, newly forming bone recovers anatomical and structural characteristics, resulting in the acceleration of the new bone growth.
10 In addition, calcium sulfate is absorbable and comparatively safe material without any inflammatory reaction.

In this invention, a gel type composition was
15 prepared by mixing powder type calcium sulfate and viscous biopolymer. The viscous biopolymer can be selected from a group consisting of carboxymethylcellulose, hyaluronic acid, chitosan, polyacrylic acids, polyvinyl ethers, polystyrenes,
20 cellulose ethers, cellulose esters, starches and polysaccharides. In the preferred embodiment of the present invention, carboxymethylcellulose was used as a viscous biopolymer.

25 The preferable proportion of powder type calcium

sulfate to viscous biopolymer for the composition of the present invention is 20:80 ~ 80:20, and the ratio of 50:50 is more preferable.

In the preferred embodiment to prepare the gel type composition of the present invention, sodium salt of polycarboxymethyl ether of cellulose can be used for carboxymethylcellulose used as a viscous biopolymer. The carboxymethylcellulose sodium salt is an odorless hydroscopic powder having various colors such as white, cream color, etc and is used for a base material. This material is used in the form of suspension or milky liquid.

Carboxymethylcellulose is also known to be a harmless protecting material used for ileostomy or colostomy (Raynolds JEF., Martindale., *The Extra Pharmacopoeia.*, 29: 1433, 1989).

The present inventors injected the mixture of calcium sulfate and viscous biopolymer into the extended area using 18-gauge needle, which was easy and time saving method not requiring secondary operation. The composition of the present invention stimulated new bone-formation by powerful mineralization 3 weeks after injection and the new bone-formation was widely observed 6 weeks after injection. In addition, the

above composition was slowly absorbed in a body after injection and finally only calcium sulfate that did not affect bone-regeneration was left during which inflammatory reaction was not caused. Thus, the composition of the present invention was confirmed to be a safe material.

The present invention also provides a use of the composition for stimulating bone-formation and bone-consolidation.

In order to confirm if the composition for bone-filling can stimulate bone-formation and bone-consolidation, the present inventors performed bone-extension at jawbone of a dog 2 mm or 1 mm per day, after which the present inventors injected the composition thereto and investigated the effect of the composition on bone-consolidation in the early stage.

As a result, it was observed that the calcification was undergoing around the extended area of jawbone in every group in which extension was induced 2 mm per day except control group, which was confirmed by radiographs taken in the 3rd week and in the 6th week after extension. Radiolucent zone was also observed between extended jawbone spicules and consolidated areas abutting on the both sides of

jawbone spicules were all different group by group. In
3rd week after bone-extension, radiodense zone was
hardly observed in a control group in which bone-
extension was induced 1 mm or 2 mm per day without
5 injection of the composition, so was in another group
in which bone extension was performed 2 mm per day with
injection of the composition while huge radiodense zone
was observed in the group in which bone-extension was
induced 1 mm per day with the injection of the
10 composition. In 6th week after bone-extension,
radiodense zone was gradually stretching to the center
of extended area both in a control group in which bone-
extension was induced 1 mm per day without injection of
the composition and a group in which bone-extension was
15 induced 1 mm or 2 mm per day with the injection of the
composition. The largest radiodense zone was observed
in the group in which bone-extension was induced 1 mm
per day with the injection of the composition while
radiodense zone was hardly seen in the control group in
20 which bone-extension was induced 2 mm per day without
the injection of the composition (see FIG. 3 - FIG. 5).

Histological test was also performed. As a
result, osteoblasts forming osteoid were observed
around the edge of extended area and many fibrous
25 tissues were also observed in the center of the

extended area in a control group in which bone-extension was induced 1 mm per day without the composition in the 3rd week after extension (see FIG. 6A). The new bone-formation became larger in that group in 6th week after extension, though the center of the extended area was filled with fibrous tissues (see FIG. 6B and 6C). In another control group in which bone-extension was induced 2 mm per day without the injection of the composition, new bone was partly observed in the extended area and most of the extended area was filled with fibrous tissues (see FIG. 7).

In the meantime, lots of active osteoblasts were observed from the edge to the center of the extended area and newly formed bone and fibrous tissues were dominant in a group in which bone-extension was induced 1 mm per day with the injection of the composition in 3rd week after extension (see FIG. 8A and 8B). The generated new bones were distributed all over the extended area just like normal cortical bones in that group in 6th week after extension (see FIG. 8C and 8D). The extended area of the group in which bone-extension was induced 2 mm per day with the injection of the composition was connected with fibrous interzone and bone-formation around the edge was observed in 3rd week after extension (see FIG. 9A and 9B). Bone-formation

was observed in half of the extended area in that group in 6th week after extension (see FIG. 9C and 9D).

As described hereinbefore, less bone-formation was observed in the group in which bone-extension was induced 2 mm per day with the injection of the composition, comparing to the group in which bone-extension was induced 1 mm per day with the injection of the composition. Thus, 1 mm extension per day is believed to be clinically more effective.

In the control group in which bone-extension was induced 1 mm per day without the injection of the composition, the extended area was not replaced with newly formed bone until the 6th week after extension and most of the extended area was filled with fibrous tissues except the edge on which partial bone-formation began. Taking the above results and the reports of Califano and Komuro into consideration (Califano L, Cortese A, Zupi A, Tajana G, *J. Oral Maxillofac. Surg.*, 1994, 52, 1179; Komuro Y, Takato T, Harii K, Yonemara Y, *Plast. Reconstr. Surg.*, 1994, 94, 152), bone-consolidation takes at least 6 weeks and the faster the extension speed is, the shorter the bone-extension period is. Fast extension is, thus, preferable as long as it does not disturb bone-formation since it can relieve suffering and prevent complications after

operation by shortening bone-consolidation period.

Generally, extended bone tends to be absorbed, so that 10 - 20% over-extension is preferable. The accurate result of the over-extension was not reported, 5 though. So, the extent of over-extension was decided by operator's experience. The adsorption of extended bone seems to depend on mineralization of the extended bone. As for an adult or an aged patient, it is 10 required to wait 6-10 weeks after bone-extension for complete bone-consolidation. However, the present inventors believe that over-extension is not necessary if the composition of the present invention is used since the composition stimulates bone-regeneration

15

From the above results, it is confirmed that the composition of the present invention can be effectively used as an economical bone-filling composition suitable for body because the composition stimulates bone- 20 formation and bone-consolidation in the early stage after bone-extension, leading to the shortening the bone-consolidation period.

EXAMPLES

Practical and presently preferred embodiments of the present invention are illustrative as shown in the following Examples.

5 However, it will be appreciated that those skilled in the art, on consideration of this disclosure, may make modifications and improvements within the spirit and scope of the present invention.

Example 1: Preparation of composition for bone-filling

10 The present inventors have prepared a composition for bone-filling by mixing carboxymethylcellulose (referred as "CMC" hereinafter) with calcium sulfate. Particularly, mixed 98.9 g of $\text{CaSO}_4 \cdot \text{H}_2\text{O}$, 0.3 g of CaCO_3 , 0.3 g of MgCO_3 and 0.5 g of $\text{CaCO}_3 \cdot \text{MgCO}_3$ together, added
15 thereof to 100 g of CMC and then suspended thereof well, resulting in the preparation of a gel type composition of the present invention.

Example 2 ~ Example 7

20 Based on the ratio presented in the below Table 1, the present inventors prepared gel type compositions with the same method as the above Example 1.

<Table 1> Composition ratio

	CaSO ₄ · H ₂ O	CaCO ₃	MgCO ₃	CaCO ₃ · MgCO ₃	Ratio to CMC
Example 2	98 g	0.5 g	0.5 g	1 g	20:80
Example 3	98 g	0.4 g	0.4 g	1.2 g	30:70
Example 4	98.5 g	0.3 g	0.2 g	1 g	40:60
Example 5	98.5 g	0.5 g	0.5 g	0.5 g	60:40
Example 6	99 g	0.3 g	0.2 g	0.5 g	70:30
Example 7	99 g	0.2 g	0.5 g	0.3 g	80:20

Experimental Example 1: Bone-extension operation

In order to confirm if the composition of the present invention stimulates bone-formation and bone-consolidation in the early stage of bone-extension, the present inventors performed bone-extension operation at jawbones of dogs. After operation, the inventors injected the composition and then observed any change.

Particularly, selected 8 5-month old dogs for experiment and grouped them by 4 for a control group and for a composition group. Divided those groups into subgroups such as a control group 1 in which bone-extension was induced 1 mm per day, a control group 2 in which bone-extension was induced 2 mm per day, a composition group 1 in which bone-extension was induced 1 mm per day, a composition group 2 in which bone-extension was induced 2 mm per day.

Kept the breath of dogs through tubes inserted in organs after general anesthesia and shaved the operating part, followed by sterilization and application. Incised skin 3-4 cm along the lower end of jawbone, lifted masseter muscle and exposed the side part of jawbone. Then, performed vertical osteotomy at the trunk of jawbone using an electric saw and completely cut jawbone. Fixed each fixing pin of external fixator on spicule 1 cm away from the cutting area right and left. While fixing the pins on the jawbone spicule with drill, kept washing with saline solution not to burn the fixing sites. Inserted the pins just as deep as it barely passed through jawbone and then fixed them tightly. After fixing two pins all, set them on bone extending apparatus (Molina Distractors, Wells Johnson Company) (FIG. 2).

Sutured the incised area with 5-0 vicryl and 5-0 nylon stitching fiber layer upon layer and recovered the dogs from anesthesia. Administered penicillin(100,000 μ /kg) by intramuscular injection every 12 hours for 7 days after operation and oral-administered anodyne every 4-6 hours to relieve pain. Fed the dogs with soft diet until the second day after operation and provided regular diet from the third day. From the fifth day after operation, started bone-

extension 1 mm per day for 10 days (control group 1 and composition group 2) or 2 mm per day for 5 days (up to 10 mm total; control group 2 and composition group 2).

On the day when bone-extension was finished,
5 injected 1 ml of the composition for bone-filling prepared in the above Example 1 into the extended area using 18 gauge needle (FIG. 1B). Meanwhile, injected only 1 ml of carboxymethylcellulose into the extended area for control groups.

10 After the injection of the composition, kept the bone-extension apparatus for 6 weeks to induce bone-consolidation and bone-regeneration. Sacrificed the first 4 dogs selected from each group by one in the 3rd week after bone-extension by injecting overdose of
15 pentobarbital (40-50 mg/kg) and so did for the rest 4 dogs in the 6th week.

<1-1> Radio-assay

Examined each animal group went through bone
20 extension with radio-assay every week and observed bone-formation and bone-consolidation through the radiographs taken after 3 weeks and 6 weeks respectively.

As a result, observed undergoing calcification in
25 the extended area of jawbone in every group except a

control group 2 (FIG. 3 - FIG. 5). Confirmed radiolucent zone in between the extended jawbone spicules and other consolidated area abutting on both sides of jawbone spicules. Hardly found radiodense zone in control groups and a composition group 2 in the 3rd week after bone-extension while observed a huge radiodense zone in a composition group 1. Confirmed that radiodense zone was stretching toward the center of the extended area in every group except a control group 2 in the 6th week after extension, and detected the largest radiodense zone in a composition group 1.

<1-2> Histological test

Bone samples were taken from extended jawbone including normal osseous tissues therearound with an electric saw. The obtained spicules were fixed in 10% neutral formalin for 1 week, and then decalcified in 10% nitric acid and 10% sodium citrate for 2 days. 4-6 μm of specimens were prepared by dehydration and paraffin-fixation following general techniques. The specimens were stained with hematoxylin-eosin to observe histological changes using an optical microscope.

As a result, osteoblasts forming osteoid were

partly found on the edge of the extended area and lots of fibrous tissues were seen in the center area in a control group 1 in the 3rd week after extension (FIG. 6A). In the 6th week after extension, newly formed bone was observed more than in the 3rd week and the center of the extended area was filled with fibrous tissues (FIG. 6B and 6C). In a control group 2, new bone-formation was partly observed in the extended area and most of the extended area was filled with fibrous tissues (FIG. 7). In a composition group 1, lots of active osteoblasts were seen over the edge and the center of the extended area and the areas were filled with newly formed bone and fibrous tissues in the 3rd week after extension (FIG. 8A and 8B). In the 6th week after extension, the new bone formed throughout the whole extended area was almost similar to the normal cortical bone (FIG. 8C and 8D). In a composition group 2, extended area was bridged by fibrous interzone and new bone-formation was observed along the edge in the 3rd week after extension (FIG. 9A and 9B). In the 6th week, newly formed bone was observed around half of the extended area (FIG. 9C and 9D).

INDUSTRIAL APPLICABILITY

As described hereinbefore, the gel type composition of the present invention induces new bone-formation, provides a normal bone-structure, prevents the growth of unnecessary connecting tissues and is
5 suitable for human enough to be substituted for bone during the recovery process as well as induces the growth of blood vessels and bony osteogenesis cells in the early stage. Therefore, the composition of the present invention can be effectively used as a bone-
10 filling material suitable for body.

What is claimed is

1. A bone-filling composition for stimulating bone-formation and bone-consolidation comprising
 - 5 1) 20~80 weight% of mixture containing CaSO_4 (90~99 weight%) and CaCO_3 , MgCO_3 , $\text{CaCO}_3 \cdot \text{MgCO}_3$ (1~10 weight%); and
 - 2) 80~20 weight% of viscous biopolymer.
- 10 2. The bone-filling composition for stimulating bone-formation and bone-consolidation as set forth in claim 1, wherein the composition comprises CaSO_4 98~99 weight%, CaCO_3 0.3~1 weight%, MgCO_3 0.3~1 weight% and $\text{CaCO}_3 \cdot \text{MgCO}_3$ 0.5~1 weight%.
- 15 3. The bone-filling composition for stimulating bone-formation and bone-consolidation as set forth in claim 1, wherein the viscous biopolymer is selected from a group consisting of
 - 20 carboxymethylcellulose, hyaluronic acid, chitosan, polyacrylic acids, polyvinyl ethers, polystyrenes, cellulose ethers, cellulose esters, starches and polysaccharides.

4. The bone-filling composition for stimulating bone-formation and bone-consolidation as set forth in claim 3, wherein the viscous biopolymer is carboxymethylcellulose.

5

5. The bone-filling composition for stimulating bone-formation and bone-consolidation as set forth in claim 1, wherein the ratio of calcium sulfate to viscous biopolymer is 50:50.

10

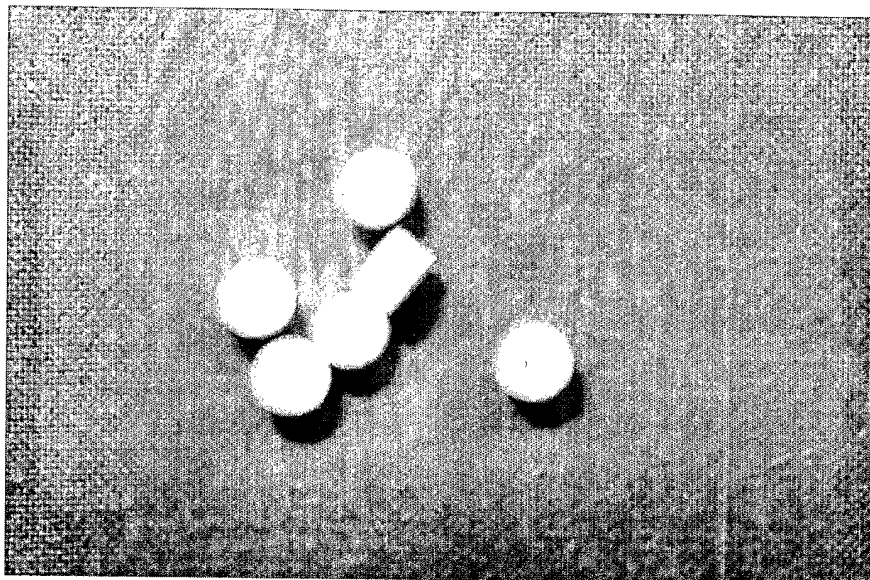
6. The bone-filling composition for stimulating bone-formation and bone-consolidation as set forth in claim 1, wherein the composition is a gel type.

15

1/14

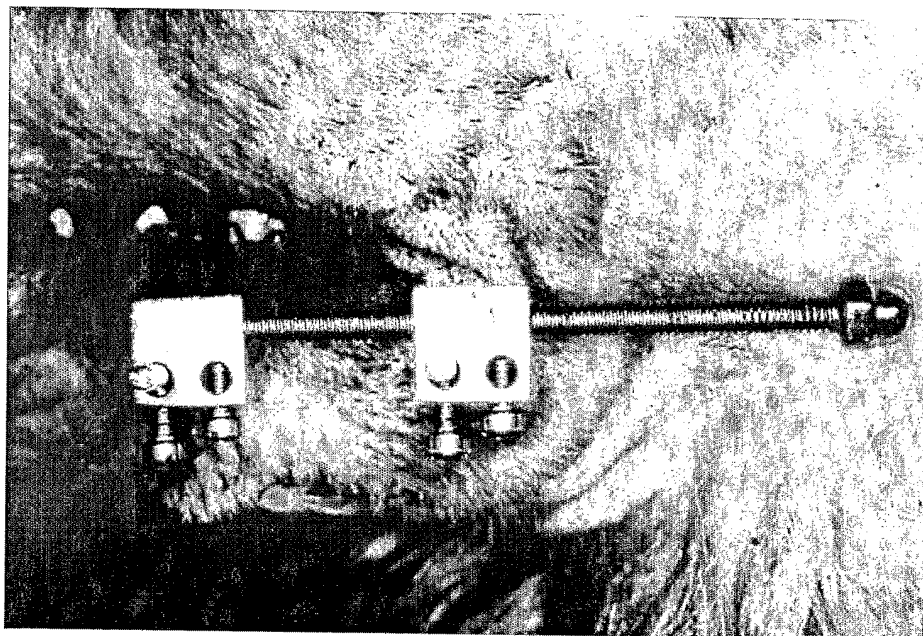
FIGURES

FIG. 1



2/14

FIG. 2

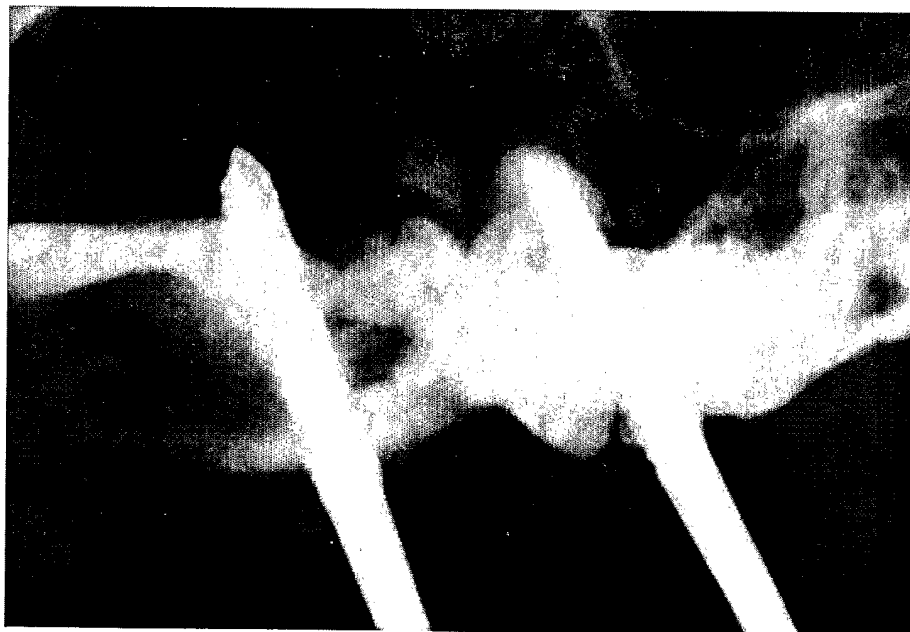


3/14

FIG. 3a

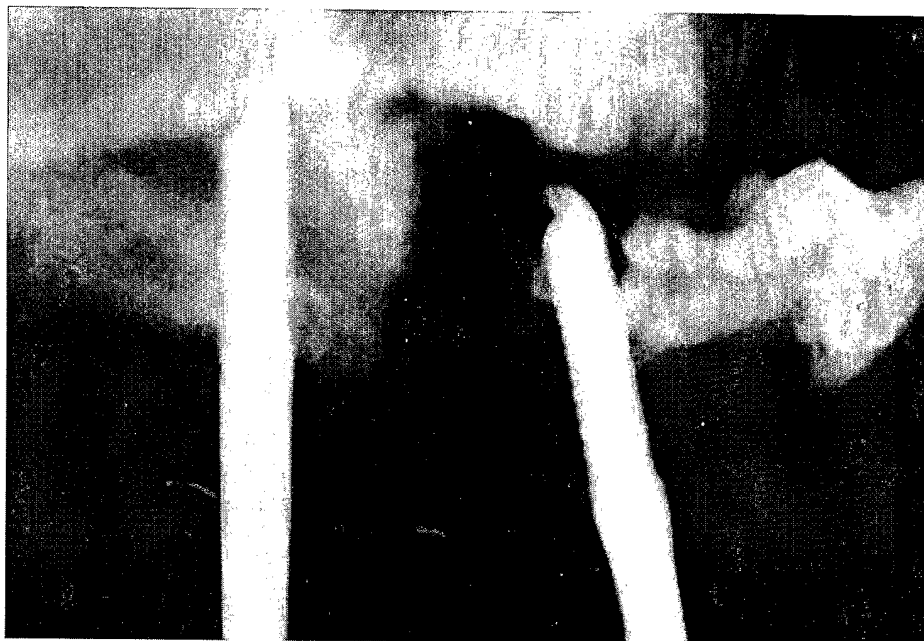

FIG. 3b



4/14

FIG. 3c

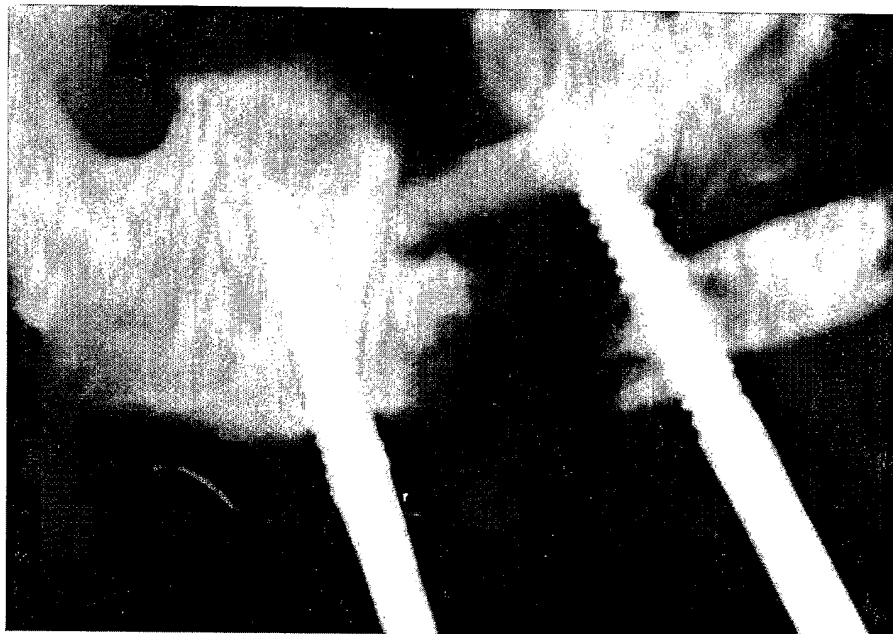
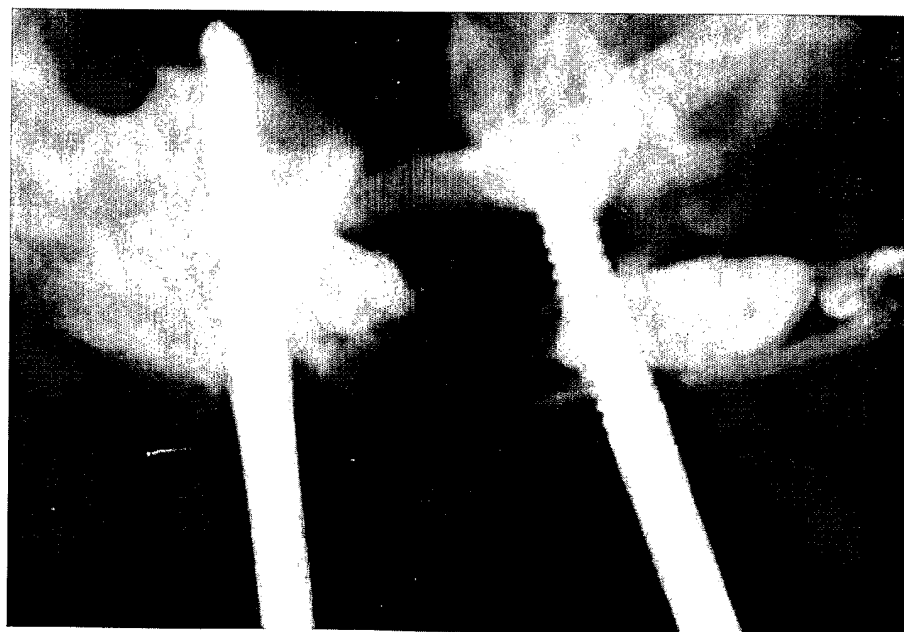


FIG. 3d

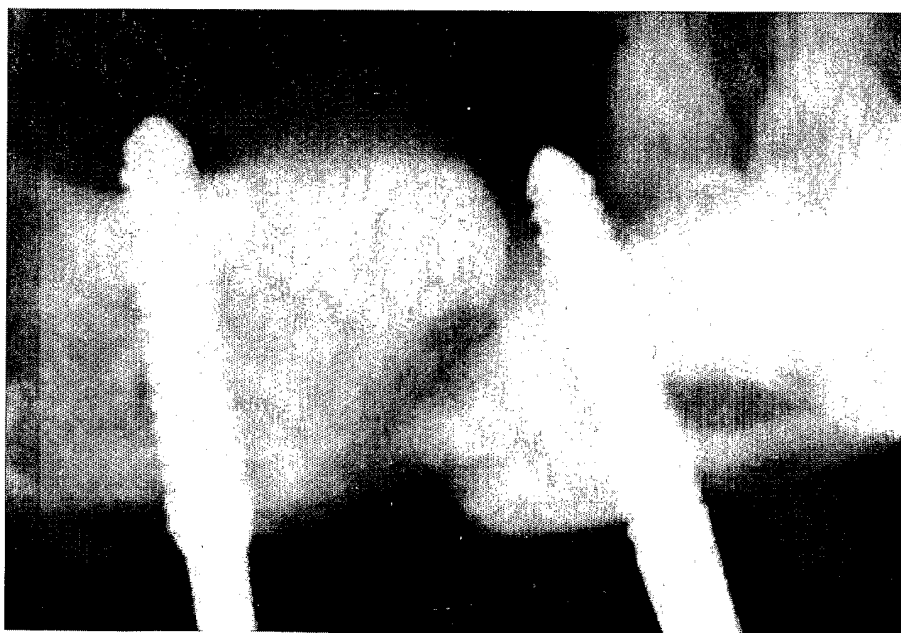


5/14

FIG. 4a

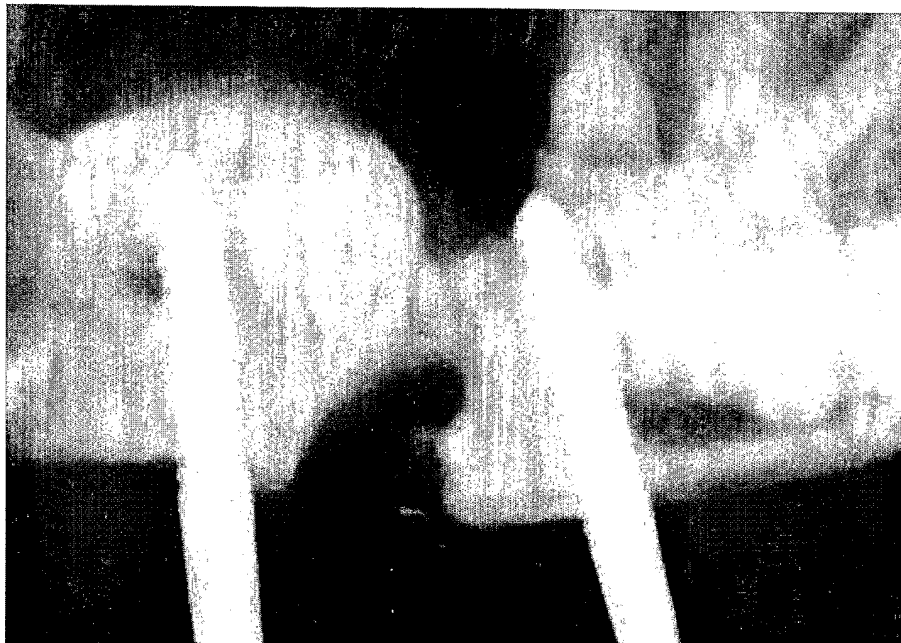

FIG. 4b



6/14

FIG. 5a

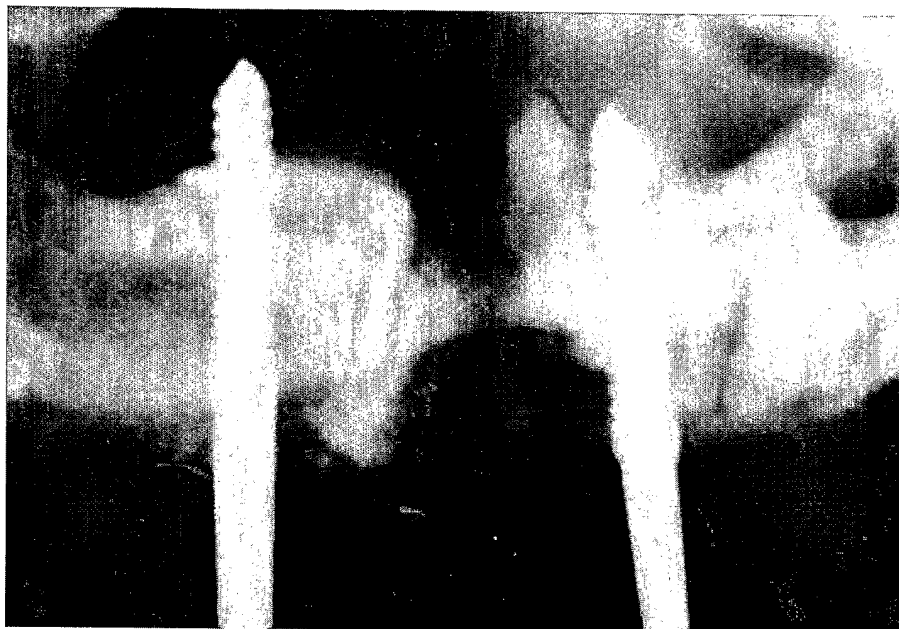
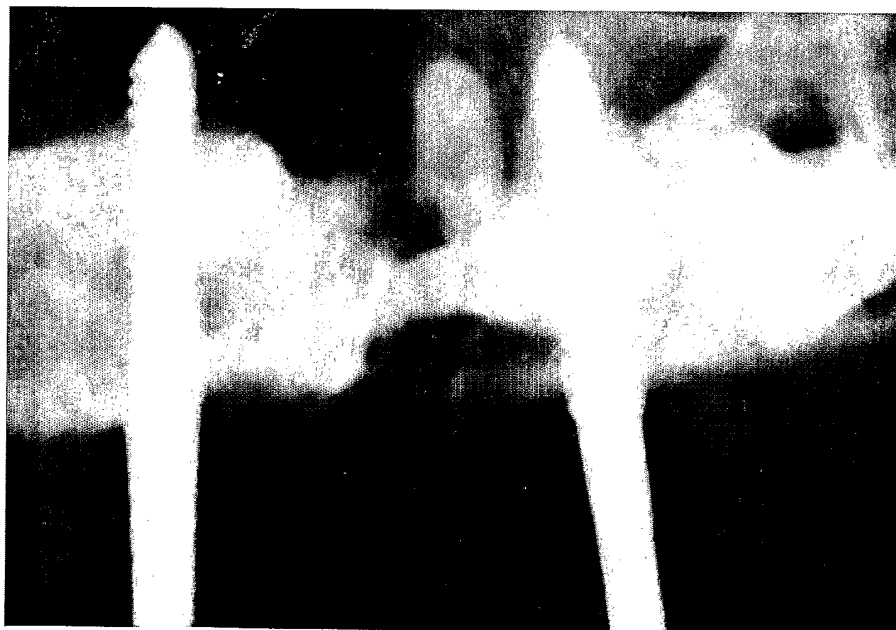


FIG. 5b



7/14

FIG. 6a

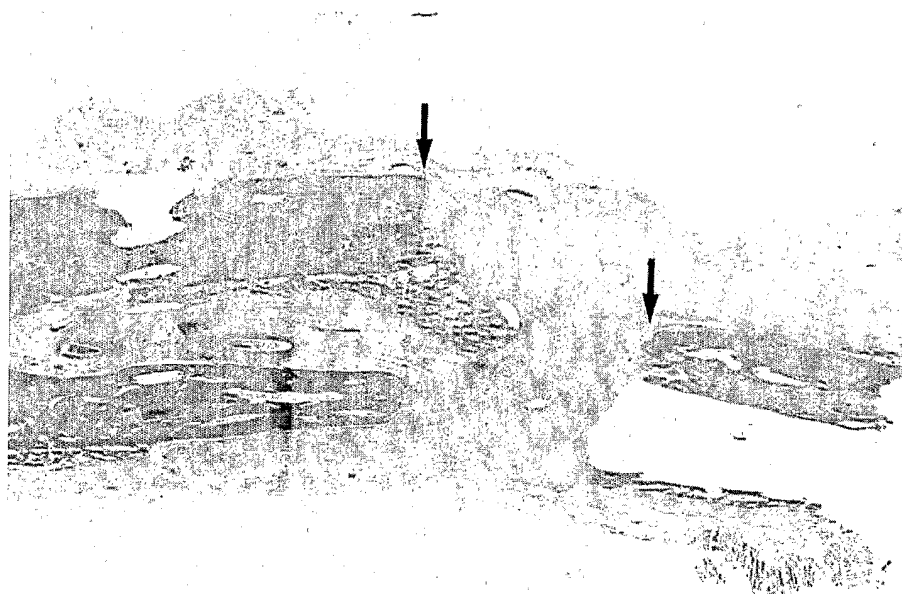

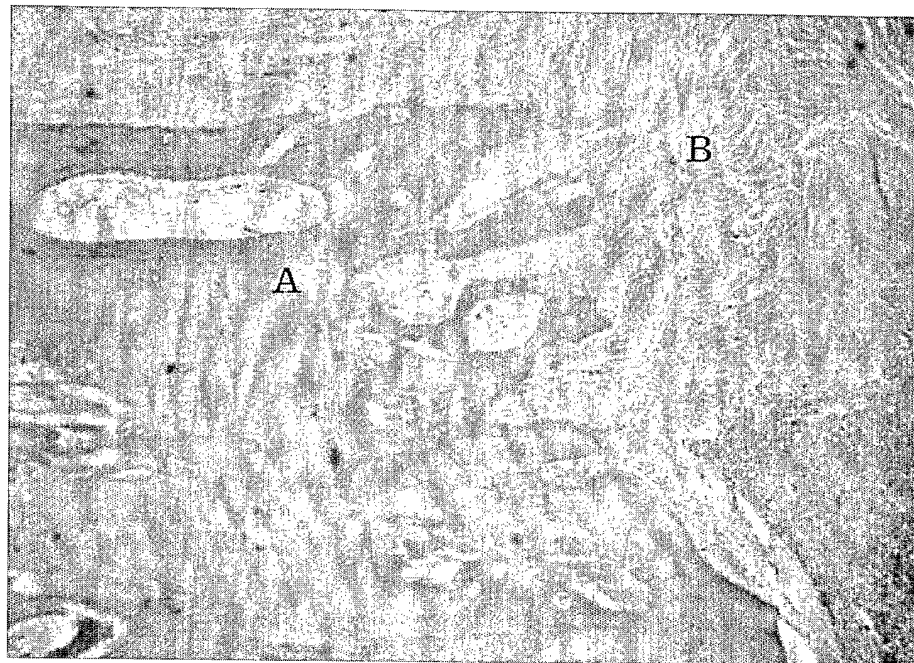


FIG. 6b



8/14

FIG. 6c

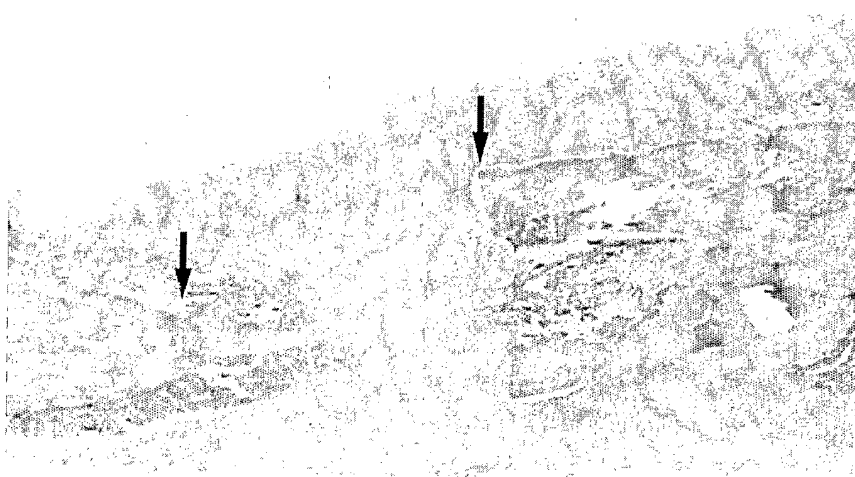


9/14

FIG. 7a

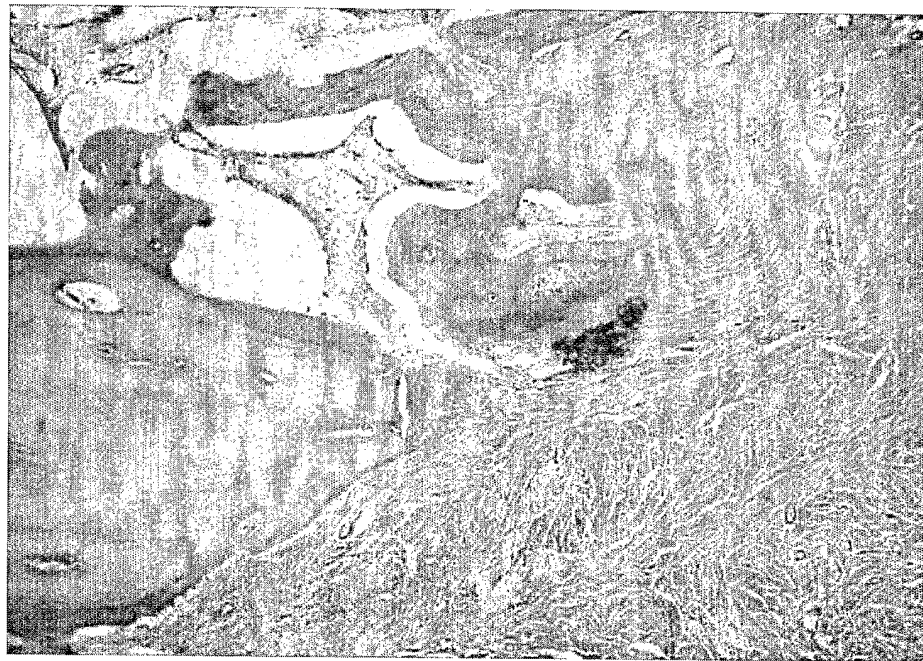


FIG. 7b



10/14

FIG. 7c

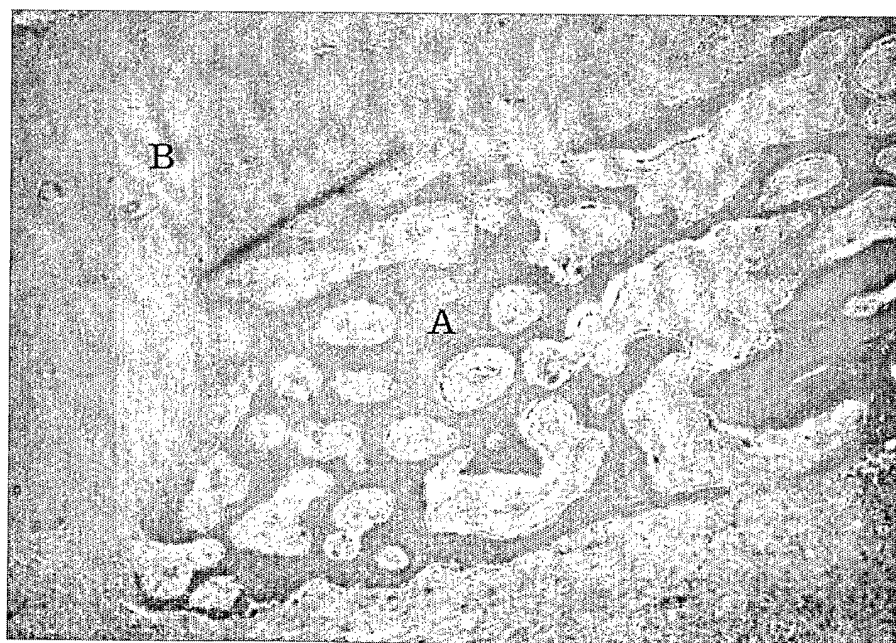


11/14

FIG. 8a



FIG. 8b

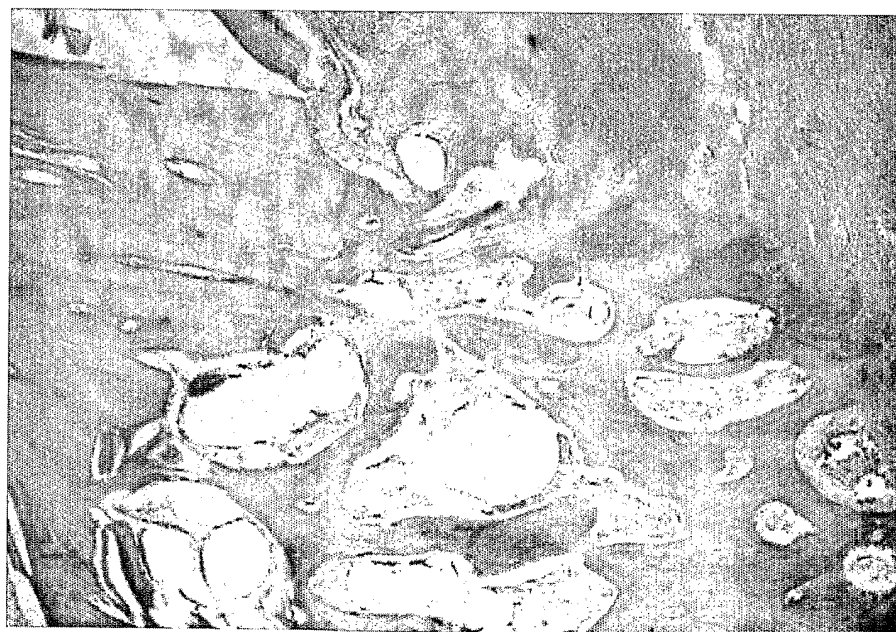

12/14

FIG. 8c




FIG. 8d



13/14

FIG. 9a


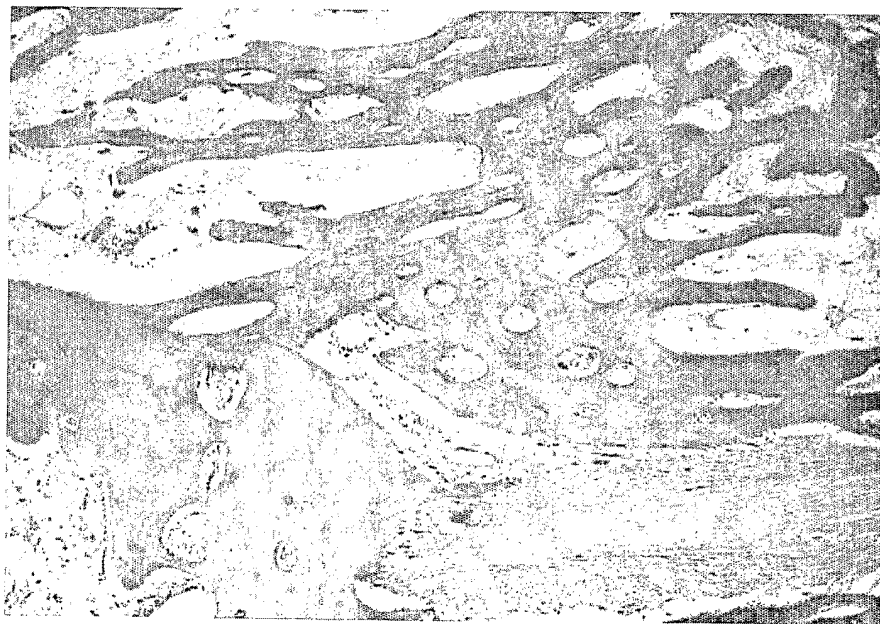


FIG. 9b

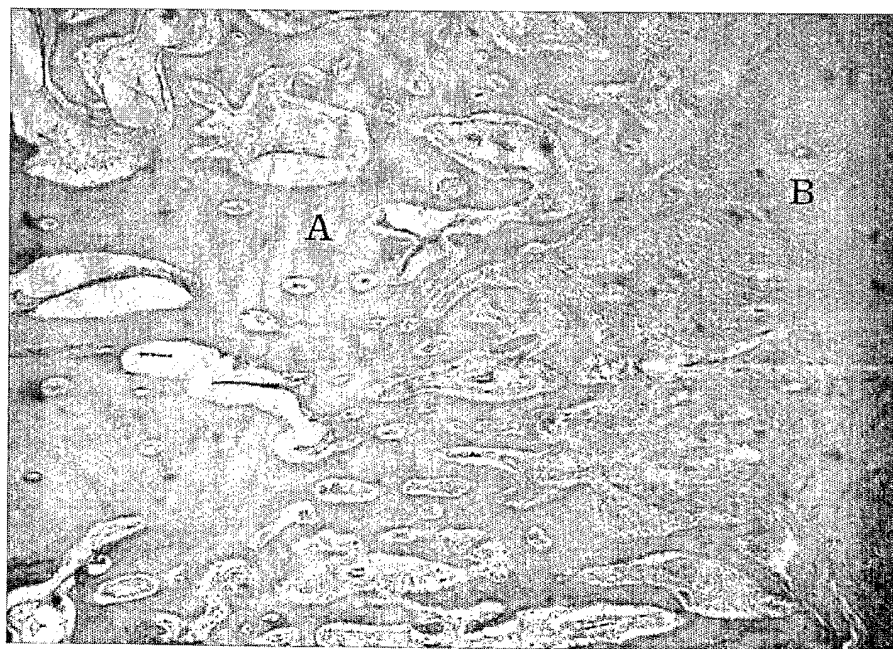


14/14

FIG. 9c

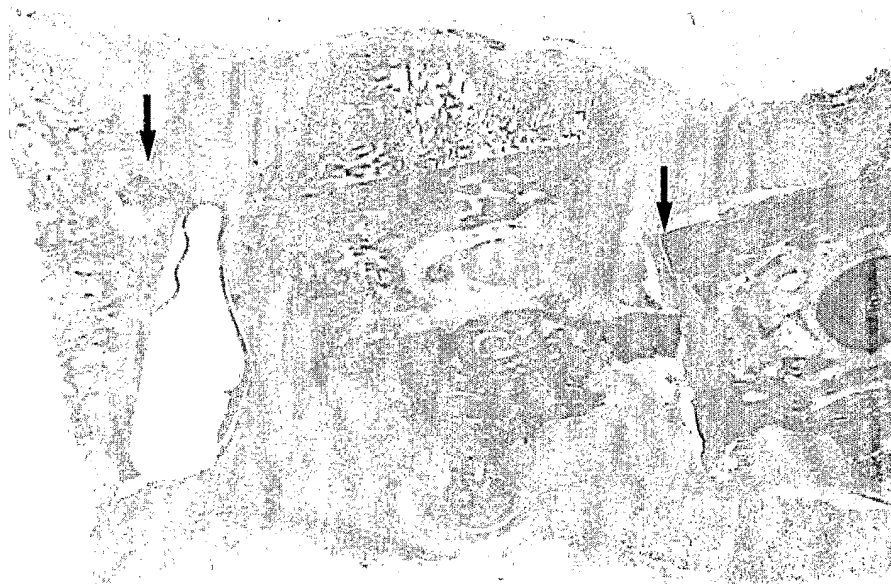

FIG. 9d



INTERNATIONAL SEARCH REPORT

International application No. -
PCT/KR02/01839**A. CLASSIFICATION OF SUBJECT MATTER****IPC7 A61L 27/44**

According to International Patent Classification (IPC) or to both national classification and IPC

B. FIELDS SEARCHED

Minimum documentation searched (classification system followed by classification symbols)

A61L 27, A61F 2, A61K 31, A61K 35, A61K 37, A61K 38, A61K9

Documentation searched other than minimum documentation to the extent that such documents are included in the fields searched

Korean Patent and Application for Invention since 1975

Korean Utility Models and Application for Utility Models since 1975

Japanese Utility Models and Application for Utility Models since 1975

Electronic data base consulted during the international search (name of data base and, where practicable, search terms used)

NCBI, eKIPASS, USPTO, INSPECT "bone filling, composition, calcium sulfate, visco*, gel, osteogenic, carrier, A61"

C. DOCUMENTS CONSIDERED TO BE RELEVANT

Category*	Citation of document, with indication, where appropriate, of the relevant passages	Relevant to claim No.
Y	US 6030635 A (Musculoskeletal Transplant Foundation) 29 Feb 2000 -see the entire document-	1, 2, 3, 4, 6
E, Y	US 6458375 B1 (Musculoskeletal Transplant Foundation) 1 Oct 2002 -see the entire document-	1, 2, 3, 4, 6
A	US 5958443 A (MDV Technologies, Inc.) 28 Sep 1999 -see the pages 5-10 and the claims-	1, 2, 3, 4, 5, 6
A	US 6326018 B1 (Musculoskeletal Transplant Foundation) 4 Dec 2001 -see the claims-	1, 2, 3, 6
A	US 5648097 A (Biotek, Inc.) 15 Jul 1997 -see the entire document-	1

 Further documents are listed in the continuation of Box C. See patent family annex.

* Special categories of cited documents:

"A" document defining the general state of the art which is not considered to be of particular relevance

"E" earlier application or patent but published on or after the international filing date

"L" document which may throw doubts on priority claim(s) or which is cited to establish the publication date of citation or other special reason (as specified)

"O" document referring to an oral disclosure, use, exhibition or other means

"P" document published prior to the international filing date but later than the priority date claimed

"T" later document published after the international filing date or priority date and not in conflict with the application but cited to understand the principle or theory underlying the invention

"X" document of particular relevance; the claimed invention cannot be considered novel or cannot be considered to involve an inventive step when the document is taken alone

"Y" document of particular relevance; the claimed invention cannot be considered to involve an inventive step when the document is combined with one or more other such documents, such combination being obvious to a person skilled in the art

"&" document member of the same patent family


Date of the actual completion of the international search

26 JUNE 2003 (26.06.2003)

Date of mailing of the international search report

27 JUNE 2003 (27.06.2003)

Name and mailing address of the ISA/KR


 Korean Intellectual Property Office
 920 Dunsan-dong, Seo-gu, Daejeon 302-701,
 Republic of Korea

Facsimile No. 82-42-472-7140

Authorized officer

JOO, Young Sik

Telephone No. 82-42-481-5995

